

Update in Ophthalmology/DME[®]

VOLUME 1, NO 1, 2017

Welcome

This is the first issue of our series of newsletters intended to appear at timely intervals to take advantage of important developments.

Update in Ophthalmology/DME presents the seasoned observations, opinions and management of Ophthalmology/DME. The aim of this Newsletter is to bring to the ophthalmologists' doorstep *Update in Ophthalmology/DME* in a concise and friendly manner. We have made every effort to search the international literature to present the most current, interesting and cutting-edge material in order to make this newsletter a respected as well as a useful tool for the everyday practice of ophthalmologists with one aim: to provide good service to their patients. The information stated and presented is the result of search in international reliable medical databases.



Sponsored by



Bayer

This material is provided as an educational service from Bayer. The facts, opinions, and ideas expressed in this material are those of the authors alone. Bayer has had no influence over the content and can not be held responsible for its scientific content.



Emirates National Committee
of right to sight

Editorial Board



Dr. Abdulrazzaq Almadani,
Consultant Endocrinologist
Al Borj Medical Centre



Dr. Buthaina Bin Belaila,
Consultant family physician,
Head of Non Communicable
Disease, Ministry Of Health &
Prevention



Dr. Fatheya Al Awadi
Head of Endocrine Department
- Dubai Hospital, Chairperson -
Diabetes Combat and Control
Committee - DHA



**Dr Fatima Ibrahim Mohammed
Al Amiri**
Specialist & Head of Ophthalmology
Department Al-Qassimi & Kuwait
Hospital, President of Emirates National
Committee of Right to Sight "Eye Health"



Prof. Constantinos Karabatsas
MD, DM, FRCSEd, As.Professor of
Ophthalmology, Athens University
of Applied Sciences, Consultant
Ophthalmic Surgeon, LaserVision.
gr, Athens, Greece



Dr. Mohammad Abdul-Nabi
Consultant Ophthalmologist
and Head of Retina & Cataract
Surgery Mafraq Hospital, Abu
Dhabi, UAE



Dr. Mohamed A. Awadalla,
MD, FRCSEd, Professor of
Ophthalmology, Cairo University,
Egypt. Consultant Ophthalmology
& VR Surgeon, MOHAP, UAE.



Dr. Mohammed Abdulwahab Al Amri
MBBS, MD, HSDO, Medical Retina Specialist,
Consultant Ophthalmologist, President of Gulf
Retina group (GRG)
Vice President of QOIC and Head of Scientific
Committee, Member of National Committee
for the Right to Sight, Adjunct professor in
Medical College of Sharjah University Head of
ophthalmic CME in Al Qassimi hospital.



Dr. Nahed Monsef
Consultant Family Medicine RCGP
Fellowship, ABFM, MSc Health
Care Management Director
of Health Affairs Department
Primary Health care Services
Sector Dubai Health Authority



Dr. Omar Al Jabri
Chief Medical Officer Ambulatory
Healthcare Services Abu Dhabi
Health Services Company (SEHA)



**Dr. Patricio
M. Aduriz-Lorenzo**
MD. DO. FRCSEd. FRCSI. FEBO.
HOD Ophthalmology & Consultant
Medical Retina. Dubai Hospital,
DHA. ESO.



Dr. Saleh Al Messabi
President of the Emirates
Society of Ophthalmology



**Dr. Wadeia Mohammad
Al Sharief**
Consultant Family Physician
President Emirates Family
Medicine Society, EMA
Dubai Health Authority

Diabetic Macular Edema

Introduction

Diabetic retinopathy (DR) is characterized by gradually progressive alterations in the retinal microvasculature, leading to areas of retinal nonperfusion, increased vascular permeability, and pathologic intra-ocular proliferation of retinal vessels. The complications associated with the increased vascular permeability, termed *macular edema*, and uncontrolled neovascularization, termed *proliferative diabetic retinopathy* (PDR), can result in severe and permanent vision loss if not treated in a timely and appropriate manner.¹

- Diabetic retinal disease remains a leading cause of new onset blindness in developed countries.
- In its earliest stages, diabetic retinopathy is asymptomatic, visual acuity may be excellent, and patients may be unaware of the presence or significance of retinopathy.
- Early institution of routine lifelong follow-up; intensive systemic control of blood glucose, hypertension, and dyslipidemia; and timely therapeutic intervention when required are the hallmarks of appropriate diabetic eye care and can prevent visual loss from diabetic retinal complications.

Update in Ophthalmology/DME is published by CCM Publishing. Editorial Office:

CCM Middle East s.a.r.l. P.O. Box 61145, 5 Konitsis str, Maroussi, Athens 15125 Greece.
Tel.: (+30) 210 6146560, Fax: (+30) 210 8061765, Email: info@groupccm.com

Senior Editor

Dr. Kamran Abbasi Editor, Journal of the Royal Society of Medicine, London, UK

Editorial Board

Dr. Abdulrazzaq Al Madani (President of Emirates Diabetes Society)

Dr. Buthaina Bin Belaïla (MOH)

Dr. Fatheya Al Awadi (Dubai Hospital-DHA)

Dr. Fatma Al Amiri (Al Qassimi Hospital, MOH)

Dr. Konstantinos Karabatsas (Optics & Optometry Dpt, Athens University of Applied Sciences)

Dr. Mohamed Abdul Nabi (Mafraq Hospital-Abu Dhabi)

Dr. Mohamed Awadalla (ESO, MOH)

Dr. Mohammed Al Amri (Al Qassimi Hospital, MOH) Ms. Mai Haider Awadalla (DHA)

Dr. Nahed AbdulKhaleq Monsef (DHA)

Dr. Omar Naseeb Al Jabri (Chief Medical Officer, Ambulatory Healthcare Services-SEHA)

Dr. Patricio M. Aduriz-Lorenzo MD. DO. FRCSEd. FRCSEd. FEBO. HOD Ophthalmology & Consultant Medical Retina. Dubai Hospital, DHA. ESO.

Dr. Saleh Al Messabi (President of the Emirates Society of Ophthalmology)

Dr. Wadeea Abdulrahim (DHA-PHC)

Managing Editor & Marketing Consultant

Mr. G. Cherfan

Deputy Managing Editor

Isabelle Boghossian CCM International, Athens, Greece

The objective of this journal is to bring our readers a series of up-to-date useful information that relates to their specialty. The editors and the publisher have taken all reasonable steps to ensure that the information presented in this publication is accurate and correct at the time of publishing. Despite these steps, the editors and publisher cannot guarantee that the information is and will remain complete and correct. Developments in the field of Medicine, may show or suggest that some or all information contained herein is incorrect, incomplete, or misleading.

Copyright © 2017 CCM Group.

All rights reserved.

No part of this publication may be reproduced, stored in a retrieval system or transmitted, in any form or by any means (electronic, mechanical, photocopying, recording, or otherwise) without prior written permission by the publisher.

Despite decades of research, there is currently no known means of preventing diabetic retinopathy, and despite effective therapies, diabetic retinopathy remains the leading cause of new-onset blindness in working-age persons in most developed countries of the world.¹ With appropriate medical and ophthalmologic care, however, more than 90% of vision loss resulting from PDR can be prevented.^{1,2} Thus, until a cure for diabetes is discovered, the primary clinical care emphasis for the prevention of vision loss is appropriately directed at early identification, accurate classification, and timely treatment of retinopathy.¹

Clinical Classification of Diabetic Retinopathy Severity

DR can be broadly classified as nonproliferative diabetic retinopathy (NPDR) and proliferative diabetic retinopathy (PDR). Lesions of NPDR include hemorrhages and/or microaneurysms (H/Ma), dot and blot hemorrhages, cotton-wool spots (CWS), hard exudates (HE), venous caliber abnormalities (VCAB), and intraretinal microvascular abnormalities (IRMA). Based on the presence and degree of retinal lesions, NPDR is clinically classified as mild, moderate, severe, or very severe NPDR. PDR is marked by ocular neovascularization as manifested by neovascularization of the disc (NVD), neovascularization elsewhere (NVE), or new vessels on the iris and anterior segment of the eye, pre-retinal hemorrhage (PRH), vitreous hemorrhage (VH), or fibrous tissue proliferation (FP). Diabetic macular edema (DME) can be present with any level of DR. DME that involves or threatens the center of the macula is classified as clinically significant macular edema. The involvement of the center of the macula has been associated with a significantly increased risk for visual loss. Accurate diagnosis of the severity of DR is essential since the risk for progression to PDR and high-risk PDR is closely correlated with each specific NPDR level. Proper diagnosis of DR severity establishes the risk for progression to sight-threatening retinopathy and appropriate clinical management both in terms of follow-up schedule and therapeutic options. For example, it is important to consider PRP as DR reaches severe NPDR, early PDR, or high-risk PDR.³

In an attempt to simplify the classification of DR, a number of experts met and created the International Clinical Disease Severity Scale for DR.^{4,5} This disease severity scale is based upon the findings of the Wisconsin Epidemiologic Study of Diabetic Retinopathy (WESDR) and the ETDRS. This new classification is simple to use, easy to remember and based on scientific evidence. There are five stages that are recognized. The first is "no apparent retinopathy". As the name implies there are no diabetic fundus changes. The second stage is "mild non-proliferative retinopathy" (NPDR). This stage is characterized by the presence of a few microaneurysms. The third stage is "moderate NPDR" which is characterized by the presence of microaneurysms, intraretinal hemorrhages or venous beading that do not reach the severity of the standard photographs 2A, 6A and 8A. "Severe NPDR",

the fourth stage, is the key level to identify. Data from the ETDRS has shown that eyes in patients with DM type 2 that reach the grade of severe NPDR have a 50% chance of developing high risk characteristics if laser treatment is not instituted.^{4,6} The diagnosis of severe NPDR is based on the 4:2:1 rule of the ETDRS.⁴ Using standard photographs 2A, 6A and 8A to compare with the fundus findings, one can easily diagnose severe NPDR. If hemorrhages of at least the magnitude of standard photograph 2A are present in all 4 quadrants, then by definition severe NPDR is present. If 2 quadrants or more have venous beading (VB) of the same magnitude or greater than standard photograph 6A, then by definition severe NPDR is present. If one or more quadrant has intraretinal microvascular abnormalities (IRMA) of the same magnitude or greater than standard photograph 8A, then by definition severe NPDR is present. The final stage is "proliferative diabetic retinopathy" (PDR). PDR is characterized by neovascularization of the disc, neovascularization of the retina, neovascularization of the iris, neovascularization of the angle, vitreous hemorrhage or tractional retinal detachment. With regards to macular edema, it should be noted if macular edema is present or absent. If it is present then it can be further classified as mild, moderate and severe depending on the distance of the exudates and thickening from the center of the fovea.^{4,5}

International Clinical DR and DME Disease Severity Scales	
Diabetic Retinopathy Severity	Findings Present on Ophthalmoscopy
No apparent DR	No abnormalities
Mild NPDR	Microaneurysm only
Moderate NPDR	More than microaneurysms only, but less than severe NPDR
Severe NPDR	Any of the following with no PDR: >20 intraretinal hemorrhages in each four quadrants definite VB in 2 or more quadrants prominent IRMA in 1 or more quadrant
PDR	One or more of: NV, VH, PRH
DR, Diabetic retinopathy; NPDR, nonproliferative diabetic retinopathy; PDR, proliferative diabetic retinopathy; VB, venous beading; IRMA, intraretinal microvascular abnormalities; NV, neovascularization; VH, vitreous hemorrhage; PRH, preretinal hemorrhage.	
From Adamis AP, Miller JW, Bernal MT, et al. Increased vascular endothelial growth factor levels in the vitreous of eyes with proliferative diabetic retinopathy. <i>Am J Ophthalmol</i> 1994;118(4):445-450.	

The International Classification DME severity scale separates eyes with apparent DME from those with no apparent thickening or lipid in the macula. For eyes with apparent DME, three categories classify DME as not threatening the center of the macula (mild), threatening the center of the macula (moderate), or involving the center of the macula (severe). The clinical disease severity scale is intended to be a practical and valid method of grading severity of DR and DME.³

International Clinical DR and DME Disease Severity Scales	
DME Disease Severity	Findings on Ophthalmoscopy
DME apparently absent	No apparent retinal thickening or HE in the posterior pole
DME apparently present	Some apparent retinal thickening or HE in the posterior pole
Mild DME	Some retinal thickening or HE in the posterior pole but distant from the center of the macula
Moderate DME	Retinal thickening or HE approaching the center of the macula but not involving the center
Severe DME	Retinal thickening or HE involving the center of the macula
DR, diabetic retinopathy; DME, diabetic macular edema; HE, hard exudates.	
From Adamis AP, Miller JW, Bernal MT, et al. Increased vascular endothelial growth factor levels in the vitreous of eyes with proliferative diabetic retinopathy. <i>Am J Ophthalmol</i> 1994;118(4):445-450.	

Pathophysiology

The earliest histologic effects of diabetes mellitus in the eye include loss of retinal vascular pericytes (supporting cells for retinal endothelial cells), thickening of vascular endothelium basement membrane, and alterations in retinal blood flow. With increasing loss of retinal pericytes, the retinal vessel wall develops microaneurysms and becomes fragile.¹

One of the most serious consequences of diabetic retinopathy is progressive loss of functional retinal capillaries. Trypsin-digest preparations of the retina show areas of acellular capillaries, or "ghost" vessels, which have lost the endothelial cells and pericytes that once lined them). When patches of such acellular capillaries, first seen early in the course of NPDR, increase and become confluent, the terminal arterioles that supply these capillaries often become occluded. Regions of acellular capillaries in histologic sections have been shown to correspond to areas of capillary nonperfusion visualized by fluorescein angiography. Adjacent to these areas of retinal ischemia, clusters of microaneurysms and hypercellular vessels often develop. It has been difficult to determine whether such vessels represent altered preexisting capillaries or neovascularization within the retina. Such vessels are described clinically as intraretinal microvascular abnormalities (IRMA), a term intended to accommodate both possibilities.⁷

Clinically, microaneurysms and small retinal hemorrhages might not always be readily distinguishable and are usually evaluated together as "hemorrhages and microaneurysms". Rheologic changes occur in diabetic retinopathy and result from increased platelet aggregation, integrin-mediated leukocyte adhesion, and endothelial damage. Disruption of the blood-retina barrier can ensue, characterized by increased vascular permeability. Subsequent leakage of blood and serum from the retinal vessels results in retinal hemorrhages, retinal edema, and hard exudates. Vision loss can follow if the fovea is affected by the leakage.¹

With time, increasing sclerosis and endothelial cell loss lead to narrowing of the retinal vessels, which decreases vascular perfusion and can ultimately lead to obliteration of the capillaries and small vessels. The resulting retinal ischemia is a potent inducer of angiogenic growth factors, as insulin-like growth factors, basic fibroblast growth factor (bFGF), hepatocyte growth factor (HGF), and VEGF. These factors promote the development of new vessel growth and retinal vascular permeability. Endogenous inhibitors of angiogenesis and vascular permeability such as pigment epithelial-derived factor (PEDF), and other VEGF independent pathways such as plasma kallikrein and erythropoietin have also been found in the eye, and these have physiologic and therapeutic potential.^{1,8,9,10}

When the retina is severely ischemic, the concentration of angiogenic growth factors can reach sufficient concentration in the anterior chamber to cause abnormal new vessel proliferation on the iris and the anterior chamber angle. Uncontrolled anterior segment neovascularization can result in neovascular glaucoma because the fibrovascular proliferation in the angle of the eye causes blockage of aqueous outflow through the trabecular meshwork.¹

Progressive capillary closure and resulting retinal ischemia are commonly associated with increasing IRMA, intraretinal hemorrhages, and venous abnormalities such as segmental dilation (venous beading). Occasionally, in cases of extensive capillary nonperfusion, the retina acquires a featureless appearance with a relative dearth of visible vessels, hemorrhages, or microvascular abnormalities. Retinal ischemia represents another cause for vision loss in NPDR, and also plays a central role in the pathogenesis of PDR by stimulating elaboration of vascular endothelial growth factor A (VEGF-A) and other angiogenic factors.⁸

Risk Factors

Duration of diabetes is closely associated with the onset and severity of diabetic retinopathy. Diabetic retinopathy is rare in prepubescent patients with T1DM, but nearly all patients with T1DM and more than 60% of patients with T2DM develop some degree of retinopathy after 20 years. In U.S. reports of patients with T2DM, approximately 20% had retinopathy at the time of diabetes diagnosis and most had some degree of retinopathy over subsequent decades. In the UKPDS study of T2DM, 35% of female subjects and 39% of male subjects had some level of diabetic retinopathy at the time of diabetes diagnosis.^{1,11,12}

Lack of appropriate glycemic control is another significant risk factor for the onset and progression of diabetic retinopathy. The DCCT demonstrated a clear relationship between hyperglycemia and diabetic microvascular complications, including retinopathy, in 1441 patients with T1DM.

In patients monitored for 4 to 9 years, the DCCT showed that intensive insulin therapy reduced or prevented the development of retinopathy by 27% as compared with conventional therapy. Additionally, intensive insulin therapy reduced the progression of diabetic retinopathy by 34% to 76% and had a substantial beneficial effect over the entire range of retinopathy severity. This improvement was achieved with an average 10% reduction in HbA_{1c} from 8% to 7.2%. These results underscore that although intensive therapy might not

prevent retinopathy completely, it reduces the risk of retinopathy onset and progression.¹

Renal disease, as manifested by microalbuminuria and proteinuria, is yet another significant risk factor for onset and progression of diabetic retinopathy. Hypertension is associated with PDR and is an established risk factor for the development of macular edema.³⁷⁶ Additionally, elevated serum lipid levels are associated with extravasated lipid in the retina (hard exudates) and vision loss.¹

Clinical Findings

Clinical findings associated with early and progressing diabetic retinopathy include hemorrhages or microaneurysms, cotton-wool spots, hard exudates, intraretinal microvascular abnormalities, and venous caliber abnormalities such as venous loops, venous tortuosity, and venous beading. Microaneurysms are saccular outpouchings of the capillary walls that can leak fluid and result in intraretinal edema and hemorrhages. The intraretinal hemorrhages can be flame-shaped or dot-blot-like in appearance, reflecting the architecture of the layer of the retina in which they occur. Flame-shaped hemorrhages occur in inner retina closer to the vitreous, and dot-blot hemorrhages occur deeper in the retina. Intraretinal microvascular abnormalities are either new vessel growth within the retinal tissue itself or shunt vessels through areas of poor vascular perfusion. It is common for intraretinal microvascular abnormalities to be located adjacent to cotton-wool spots. Cotton-wool spots are caused by microinfarcts in the nerve fiber layer of the retina. Venous caliber abnormalities are generally a sign of severe retinal hypoxia. In some cases of extensive vascular loss, however, the retina might actually appear free of nonproliferative lesions. Such areas are termed *featureless retina* and are a sign of severe retinal hypoxia.¹

Vision loss from diabetic retinopathy generally results from persistent nonclearing vitreous hemorrhage, traction retinal detachment, or DME. Neovascularization with fibrous tissue contraction can distort the retina and lead to traction retinal detachment. The new vessels can bleed, causing preretinal or vitreous hemorrhage. The most common cause of vision loss from diabetes, however, is macular disease and macular edema. Macular edema is more likely to occur in patients with T2DM, which represents 90% to 95% of the diabetic population. In diabetic macular disease, macular edema involving the fovea or nonperfusion of the capillaries in the central macula is responsible for the loss of vision.¹

Epidemiology and Impact

By 2035, it is estimated that 592 million persons worldwide will have diabetes.^{1,13} There is a higher risk of more frequent and severe ocular complications in T1DM.^{1,14} Approximately 25% of patients with T1DM have retinopathy after 5 years, and this figure increases to 60% and 80% after 10 and 15 years, respectively. Because T2DM accounts for 90% to 95% of the diabetic population, type 2 disease accounts for a higher fraction of patients with vision loss. The most threatening form of retinopathy (PDR) is present in approximately 67% of T1DM patients who have had diabetes for 35 years.^{1,15}

The DCCT demonstrated that both the rate of development of any retinopathy and the rate of retinopathy progression once it was present were significantly reduced after 3 years of intensive insulin therapy.^{1,16} Interestingly, the effect of reducing the HbA_{1c} in this group from 9.1% for conventional treatment to the 7.3% for intensive treatment has resulted in a benefit maintained through 7 years of follow-up, even though the difference in mean HbA_{1c} levels of the two former randomized treatment groups was only 0.4% at 1 year ($p < 0.001$), continued to narrow, and became statistically nonsignificant by 5 years (8.1% vs. 8.2%, $p = 0.09$). The further rate of progression of complications from their levels at the end of the DCCT remains less in the former intensive treatment group. Thus, the benefits of 6.5 years of intensive treatment extend well beyond the period of its most intensive implementation.^{1,17}

Prevalence

Diabetic macular edema is now the most prevalent vision-threatening form of diabetic retinopathy in developed countries, particularly among adults with type 2 diabetes.^{18,19} Prevalence estimates for diabetic macular edema have been reported in several population-based studies in type 1 diabetes (4.2–7.9%), and type 2 diabetes (1.4–12.8%).^{18,20}

In a meta-analysis, investigators estimated the global prevalence of diabetic macular edema to be 6.8% in people with diabetes aged 20–79 years.^{18,21} Therefore, about one in 15 people with diabetes have diabetic macular edema, and more than 20 million people worldwide are affected. In the USA, the national prevalence was 3.8% based on the 2005–08 National Health and Nutrition Examination Survey,^{18,22} which is twice as common as proliferative diabetic retinopathy.^{18,23} In China, reported prevalence estimates are 3.5% in rural and 2.6% in urban populations.^{18,24} In Singapore, a newly urbanized Asian country, the prevalence is estimated to be 5.9% for Chinese, 5.7% for Malays, and 7.2% for Indians.^{18,25,26}

Incidence

Population-based data for the incidence of diabetic macular edema are scarce. In the USA, data from the Wisconsin Epidemiologic Study of Diabetic Retinopathy (WESDR) showed that the overall 10-year incidence was 20% for people with type 1 diabetes and up to 25% for people with type 2 diabetes.^{18,27} The 25-year follow-up of the WESDR type 1 diabetes cohort showed that 29% had developed diabetic macular edema.^{18,28}

WESDR showed that incidence of diabetic macular edema was mostly constant in the first 15 years of follow-up, but lower in the last 10 years, suggesting that rates might be falling.^{18,28} However, this observation might reflect better diabetes management among its participants over time, or might be related to selection bias due to selective mortality.¹⁸

Screening

Screening plays an important role in early detection and intervention to prevent the progression of DR, as low vision/blindness is substantially reduced among people with diabetes who receive recommend-

ed levels of care.^{29,30, 75} Despite the high level of clinical efficacy and cost effectiveness of DR screening and treatment, problems remain with screening and treatment compliance. Many people with diabetes do not access regular eye examinations.²⁹

Successful distribution of comprehensive guidelines to ophthalmologists and optometrists in many locations has not resulted in any significant impact on management practices for DR, and recommendations for screening and examination have been poorly followed.^{29,31,32} A 52% rate of compliance with screening guidelines has been measured in the U.S. population^{29,33} and an Australian study found that 50% of individuals with diabetes had not seen an eye care professional in the previous 2 years.²⁹ In Canada, only 32% of people with type 2 diabetes met the Canadian Diabetes Association^{29,34} guideline-recommended schedule of evaluation for DR.²⁹

Factors affecting nonadherence to recommended guidelines are numerous. They include lack of awareness that DR can lead to blindness or that severe retinopathy can be asymptomatic. Limited access to eye care professionals, particularly in remote areas can play a significant role. Fear of laser treatment, guilt about poor diabetes control causing retinopathy, the inconvenience of regular attendance, limited personal mobility due to poor overall health, and self-reported apathy may also deter patients from attending screening.²⁹

Initiation of Screening in People with Type 1 Diabetes

In type 1 diabetes, sight-threatening retinopathy is very rare in the first 5 years of diabetes or before puberty.^{29,35,36} However, almost all patients with type 1 diabetes develop retinopathy over the subsequent 2 decades^{29,37} and duration of diabetes is strongly associated with the development and severity of DR.^{29,38}

Based on the available evidence, for individuals with type 1 diabetes diagnosed after puberty, screening for DR should be initiated 5 years after the diagnosis of diabetes. For individuals diagnosed with type 1 diabetes before puberty, screening for DR should be initiated at puberty, unless there are other considerations that would suggest the need for an earlier exam.²⁹

Initiation of Screening in People with Type 2 Diabetes

Duration of diabetes is the strongest risk factor linked to the development of retinopathy.^{29,39} The risk is continuous with no evident glycemic threshold. In addition, retinopathy is often found in individuals with other microvascular complications such as neuropathy and nephropathy.²⁹

At the time diabetes is diagnosed, up to 3% of persons who develop diabetes over age 30 have CSME or high-risk DR findings. After a 10-year duration of diabetes, 7% of persons with diabetes were shown to have retinopathy, rising to 90% after 25 years. Proliferative disease was found in 20% of people with diabetes who had the disease for more than 20 years. DR prevalence was shown to be lower in patients diagnosed with diabetes after age 70, and patients with DR had a significantly higher median duration of diabetes (5.0 years) than those without DR (3.5 years).²⁹

Reports have suggested that the interval between the onset of type 2 diabetes and its diagnosis is 4–7 years. Given this and the fore-

going information, screening for DR in people with type 2 diabetes should be initiated at the time of diagnosis.²⁹

Screening Intervals for People with Diabetes

Type 1 diabetes

The EURODIAB Prospective Complications Study found that diabetes duration, onset before 12 years of age, and metabolic control were significant predictors of progression, even when adjusted for presence of baseline retinopathy.^{29,40}

Without retinopathy

Available evidence indicates that annual screening needs be carried out.^{29,41}

With retinopathy

In the presence of any NPDR, patients should be examined at 3- to 6-month intervals according to the DR severity.^{29,42}

After treatment

After laser or surgical treatment for DR, examination intervals for follow-up should be tailored to the residual DR severity level.

Type 2 diabetes

Without retinopathy

In the absence of any DR, screening intervals of 19–24 months, compared with screening intervals of 12–18 months, are not associated with an increased risk of referable retinopathy.^{29,43}

With retinopathy

Once NPDR is detected, examination should be conducted at least annually for mild NPDR, or more frequently (at 3- to 6-month intervals), for moderate NPDR according to DR severity level.^{29,44 7}

After treatment

After laser or surgical treatment for DR, screening intervals should be tailored to the residual DR severity level.

Evaluation tools

A screening evaluation for DR should include measurement of visual acuity, intraocular pressure and an evaluation to look for the presence of neovascularization of the iris and angle. Pupils should be dilated for the fundus examination, except where non-mydratric photography is used. Adequate sensitivity and specificity are required for the technique chosen. A comprehensive examination by a trained examiner should yield a sensitivity of 87% and a specificity of 94% in detecting DR. Using a photographic approach, the minimum sensitivity (compared with 7-field stereoscopic photographs read by trained graders) required for screening for DR has been suggested to be 80% or, in the case of repeated examinations that would detect DR missed at earlier examinations, 60%. Specificity levels of 90%–95% and technical failure rates of 5%–10% are considered appropriate. It must be kept in mind that the lower the sensitivity and specificity of any given screening technique the higher the potential cost to the system and the patient, through missed treatment opportunities and the potential need for additional visits.²⁹

Biomicroscopy

Slit lamp biomicroscopy with a 90D or 78D lens after pupil dilation is the current accepted routine practice for DR detection (sensitivity of 87.4% and specificity of 94.4%), and is preferred to direct ophthalmoscopy, which has lower and more variable sensitivity even when

done by an experienced examiner (sensitivity 56%–98%, specificity 62%–100%). Use of contact lens biomicroscopy or OCT should be considered if the findings are equivocal, particularly if there is unexplained vision reduction. Training should ensure examiners have sufficient diagnostic accuracy, and adequate sensitivity and specificity.^{29,45}

Retinal photography

Stereoscopic 7-field fundus 35-mm photography evaluated by a trained grader is the gold standard method of detecting DR and has been used in most of the large clinical trials in this area. However, it is costly and time consuming, and is rarely used in routine practice. Digital retinal photography is increasingly used in DR screening. On its own, it is not a substitute for a comprehensive eye examination, as other pathology may be missed, but there is high-level evidence that it can serve as a screening tool to identify patients with DR who require further evaluation and management.^{29,46,47,48} Fundus imaging has the additional advantage of being perceived by patients as a valuable educational resource. It can be carried out with dilated pupils or with undilated pupils using non-mydratric cameras.^{29,49} The chosen technology, along with the number of fields examined will influence the sensitivity of screening.^{29,50} In 1 representative study, the sensitivity for detecting sight-threatening retinopathy using a single camera field with mydriasis was measured at 82%, compared with 67% without mydriasis. By using 2 45° camera fields, an increase in sensitivity was measured to 95% with mydriasis and 54%–80% without mydriasis. Specificity was high (99%) and similar in all groups.^{29,50}

The detection of retinopathy by photographs and digital images read by various healthcare professionals generally reaches sensitivities of at least 80%, comparable to levels reached by experienced clinicians using ophthalmoscopy.²⁹

Fluorescein angiography

Fluorescein angiography has no role in screening for DR. It is an invasive examination with an inherent small risk of significant side effects, from mild and transient to severe such as anaphylaxis or cardiac arrest.²⁹

Optical coherence tomography

OCT is a noncontact, noninvasive technique that produces cross-sectional images of the retina and optic disc similar to histological sections. It has an axial resolution of 10 µm (or better with newer instruments) and provides qualitative and quantitative data that correlate well with fundus stereophotography or biomicroscopy to diagnose DME. OCT may, in fact, be superior to biomicroscopy in detecting small amounts of retinal thickening. It has good reproducibility and provides accurate measurements of retinal thickness. OCT seems useful to detect macular thickening in the early stages of DR in patients with retinopathy with vision less than 20/25 and no clinical evidence of macular edema, enabling closer follow-up for eyes with early centre-involving DME. However, OCT does not help in predicting which eyes with sub-clinical DME (macular edema less than the ETDRS definition or centre-involving macular edema detected by OCT, yet clinically undetectable) will progress to clinically significant DME as defined by the ETDRS. OCT has been incorporated as a routine measure in numerous ongoing studies of new treatments for DR.²⁹

Current data suggest that there is little reason to obtain OCT routinely in eyes with diabetes and no retinopathy, or mild to moderate DR with vision better than 20/30 when clinical examination fails to show evidence of macular edema.²⁹

References

- 1 Brownlee M, Aiello LP, Cooper ME, Vinik AI, Plutzky J, Boulton AJM. Complications of Diabetes Mellitus. Complications of Diabetes Mellitus. In: *Williams Textbook of Endocrinology*, Chapter 33, 1484-1581. Copyright © 2016 by Elsevier, Inc. All rights reserved.
- 2 Ferris FL: How effective are treatments for diabetic retinopathy? *JAMA* 1993; 269: pp. 1290-1291
- 3 Aiello LP, Silva P, Cavallerano JD, Klein R. Diabetic Eye Disease. In *Endocrinology: Adult and Pediatric*, Chapter 52, 907-919.e5. Copyright © 2016, 2010, 2006, 2001, 1995, 1989, 1977 by Saunders, an imprint of Elsevier Inc
- 4 Wu L, Fernandez-Loaiza P, Sauma J, Hernandez-Bogantes E, Masis M. Classification of diabetic retinopathy and diabetic macular edema. *World J Diabetes*. 2013 Dec 15; 4(6): 290-294.
- 5 Wilkinson CP, Ferris FL, Klein RE, Lee PP, Agardh CD, Davis M, Dills D, Kampik A, Parajasegaram R, Verdaguer JT. Proposed international clinical diabetic retinopathy and diabetic macular edema disease severity scales. *Ophthalmology*. 2003;110:1677-1682
- 6 Ferris F. Early photocoagulation in patients with either type I or type II diabetes. *Trans Am Ophthalmol Soc*. 1996;94:505-537.
- 7 Wiley HE, Chew EY, Ferris FL. Nonproliferative Diabetic Retinopathy and Diabetic Macular Edema. In *Ryan's Retina*, 50, 1061-1090. Sixth Edition © 2018, Elsevier Inc. All rights reserved.
- 8 Duh EJ, Yang HS, Suzuma I, et al: Pigment epithelium-derived factor (PEDF) suppresses ischemia-induced retinal neovascularization and VEGF-induced migration and growth. *Invest Ophthalmol Vis Sci* 2002; 43: pp. 821-829
- 9 Gao BB, Clermont A, Rook S, et al: Extracellular carbonic anhydrase mediates hemorrhagic retinal an cerebral vascular permeability through prekallikrein activation. *Nat Med* 2007; 13: pp. 181-188
- 10 Phipps JA, Clermont AC, Sinha S, et al: Plasma kallikrein mediates angiotensin II type 1 receptor-stimulated retinal vascular permeability. *Hypertension* 2009; 53: pp. 175-181
- 11 Klein R, Klein BE, Moss SE, et al: The Wisconsin Epidemiologic Study of Diabetic Retinopathy: III. Prevalence and risk of diabetic retinopathy when age at diagnosis is 30 or more years. *Arch Ophthalmol* 1984; 102: pp. 527-532
- 12 Kohner EM, Aldington SJ, Stratton IM, et al: United Kingdom Prospective Diabetes Study, 30: diabetic retinopathy at diagnosis of non-insulin-dependent diabetes mellitus and associated risk factors. *Arch Ophthalmol* 1998; 116: pp. 297-303
- 13 Guariguata L, Whiting DR, Hambleton I, et al: Global estimates of diabetes prevalence for 2013 and projections for 2035. *Diabetes Res Clin Pract* 2014; 103: pp. 137-149
- 14 Harris MI, Hadden WC, Knowler WC, and Bennett PH: Prevalence of diabetes and impaired glucose tolerance and plasma glucose levels in US population aged 20-74 years. *Diabetes* 1998; 36: pp. 523-534
- 15 Klein R, Klein BE, Moss SE, et al: The Wisconsin Epidemiologic Study of Diabetic Retinopathy: II. Prevalence and risk of diabetic retinopathy when age at diagnosis is less than 30 years. *Arch Ophthalmol* 1984; 102: pp. 520-536
- 16 Design and methodologic considerations for the feasibility phase. *Diabetes* 1986; 35: pp. 530-545
- 17 Retinopathy and nephropathy in patients with type 1 diabetes four years after a trial of intensive therapy. *N Engl J Med* 2000; 342: pp. 381-389
- 18 Tan GS, Cheung N, Simó R, Cheung GCM, Wong TY. Diabetic macular oedema. *Lancet Diabetes & Endocrinology*. 2017;5(2):143-155
- 19 Cheung N, Mitchell P, and Wong TY: Diabetic retinopathy. *Lancet* 2010; 376: pp. 124-136
- 20 Lee R, Wong TY, and Sabanayagam C: Epidemiology of diabetic retinopathy, diabetic macular edema and related vision loss. *Eye Vis (Lond)* 2015; 2: pp. 17
- 21 Yau JW, Rogers SL, Kawasaki R, et al: Global prevalence and major risk factors of diabetic retinopathy. *Diabetes Care* 2012; 35: pp. 556-564
- 22 Ding J, and Wong TY: Current epidemiology of diabetic retinopathy and diabetic macular edema. *Curr Diab Rep* 2012; 12: pp. 346-354
- 23 Zhang X, Saaddine JB, Chou CF, et al: Prevalence of diabetic retinopathy in the United States, 2005-2008. *JAMA* 2010; 304: pp. 649-656
- 24 Ding J, and Wong TY: Current epidemiology of diabetic retinopathy and diabetic macular edema. *Curr Diab Rep* 2012; 12: pp. 346-354
- 25 Wong TY, Cheung N, Tay WT, et al: Prevalence and risk factors for diabetic retinopathy: the Singapore Malay Eye Study. *Ophthalmology* 2008; 115: pp. 1869-1875
- 26 Zheng Y, Lamoureux EL, Lavanya R, et al: Prevalence and risk factors of diabetic retinopathy in migrant Indians in an urbanized society in Asia: the Singapore Indian Eye Study. *Ophthalmology* 2012; 119: pp. 2119-2124
- 27 Klein R, Klein BEK, Moss SE, and Cruickshanks KJ: The Wisconsin Epidemiologic Study of Diabetic Retinopathy XV: the long-term incidence of macular edema. *Ophthalmology* 1995; 102: pp. 7-16
- 28 Klein R, Knudtson MD, Lee KE, Gangnon R, and Klein BEK: The Wisconsin Epidemiologic Study of Diabetic Retinopathy XXIII: the twenty-five-year incidence of macular edema in persons with type 1 diabetes. *Ophthalmology* 2009; 116: pp. 497-503
- 29 Hooper P, Boucher MC, Cruess A, Dawson KG, Delperio W, Greve M, Kozousek V, Lam WC, Maberley DAL. Excerpt from the Canadian Ophthalmological Society evidence-based clinical practice guidelines for the management of diabetic retinopathy. *Can J Ophthalmol*. 2017 Nov;52 Suppl 1:S45-S74. doi: 10.1016/j.jcjo.2017.09.027.
- 30 Sloan F.A., Grossman D.S., and Lee P.P.: Effects of receipt of guideline-recommended care on onset of diabetic retinopathy and its progression. *Ophthalmology* 2009; 116: pp. 1515-1521
- 31 Schoenfeld E.R., Greene J.M., Wu S.Y., and Leske M.C.: Patterns of adherence to diabetes vision care guidelines: Baseline findings from the Diabetic Retinopathy Awareness Program. *Ophthalmology* 2001; 108: pp. 563-571
- 32 McCarty C.A., Taylor K.I., McKay R., and Keeffe J.E.: Diabetic retinopathy: effects of national guidelines on the referral, examination and treatment practices of ophthalmologists and optometrists. *Clin Experiment Ophthalmol* 2001; 29: pp. 52-58
- 33 Tseng V.L., Greenberg P.B., Scott I.U., and Anderson K.L.: Compliance with the American Academy of Ophthalmology Preferred Practice Pattern for Diabetic Retinopathy in a resident ophthalmology clinic. *Retina* 2010; 30: pp. 787-794
- 34 Canadian Diabetes Association clinical practice guidelines for the prevention and management of diabetes in Canada. *Can J Diabetes* 2003; 27: pp. S1-S152
- 35 Raman V., Campbell F., Holland P, et al: Retinopathy screening in children and adolescents with diabetes. *Ann NY Acad Sci* 2002; 958: pp. 387-389
- 36 Goldstein D.E., Blinder K.J., Ide C.H., et al: Glycemic control and development of retinopathy in youth-onset insulin-dependent diabetes mellitus. *Ophthalmology* 1993; 100: pp. 1125-113
- 37 Orchard T.J., Dorman J.S., Maser R.E., et al: Prevalence of complications in IDDM by sex and duration. *Diabetes* 1990; 39: pp. 1116-1124
- 38 Younis N., Broadbent D.M., Vora J.P., and Harding S.P.: Incidence of sight-threatening retinopathy in patients with type 2 diabetes in the Liverpool Diabetic Eye Study: a cohort study. *Lancet* 2003; 361: pp. 195-200
- 39 The prevalence of retinopathy in impaired glucose tolerance and recent-onset diabetes in the Diabetes Prevention Program. *s* 2007; 24: pp. 137-144
- 40 Porta M., Sjoelie A.K., Chaturvedi N., et al: Risk factors for progression to proliferative diabetic retinopathy in the EURODIAB Prospective Complications Study. *Diabetologia* 2001; 44: pp. 2203-2209
- 41 Mohamed Q., Gillies M.C., and Wong T.Y.: Management of diabetic retinopathy: a systematic review. *JAMA* 2007; 298: pp. 902-916
- 42 Klein R, Klein B.E., Moss S.E., and Cruickshanks K.J.: The Wisconsin Epidemiologic Study of Diabetic Retinopathy: XVII. *Ophthalmology* 1998; 105: pp. 1801-1815
- 43 Misra A., Bachmann M.O., Greenwood R.H., et al: Trends in yield and effects of screening intervals during 17 years of a large UK community-based diabetic retinopathy screening programme. *Diabet Med* 2009; 26: pp. 1040-1047
- 44 Younis N., Broadbent D.M., Vora J.P., and Harding S.P.: Incidence of sight-threatening retinopathy in patients with type 2 diabetes in the Liverpool Diabetic Eye Study: a cohort study. *Lancet* 2003; 361: pp. 195-200
- 45 Hutchinson A., McIntosh A., Peters J., et al: Effectiveness of screening and monitoring tests for diabetic retinopathy—a systematic review. *Diabet Med* 2000; 17: pp. 495-506
- 46 Vujosevic S., Benetti E., Massignan F., et al: Screening for diabetic retinopathy: 1 and 3 non-mydiatic 45-degree digital fundus photographs vs 7 standard early treatment diabetic retinopathy study fields. *Am J Ophthalmol* 2009; 148: pp. 111-118
- 47 Williams G.A., Scott I.U., Haller J.A., Maguire A.M., Marcus D., and McDonald H.R.: Single-field fundus photography for diabetic retinopathy screening: a report by the American Academy of Ophthalmology. *Ophthalmology* 2004; 111: pp. 1055-1062
- 48 Boucher M.C., Gresset J.A., Angioi K., and Olivier S.: Effectiveness and safety of screening for diabetic retinopathy with two non-mydiatic digital images compared with the seven standard stereoscopic photographic fields. *Can J Ophthalmol* 2003; 38: pp. 557-568
- 49 Cavallerano J.D., Aiello L.P., Cavallerano A.A., et al: Non-mydiatic digital imaging alternative for annual retinal examination in persons with previously documented no or mild diabetic retinopathy. *Am J Ophthalmol* 2005; 140: pp. 667-673
- 50 Baeza M., Orozco-Beltrán D., Gil-Guillen V.F., et al: Screening for sight threatening diabetic retinopathy using non-mydiatic retinal camera in a primary care setting: to dilate or not to dilate. *Int J Clin Pract* 2009; 63: pp. 433-438

International News

Hemorrhage and/or Microaneurysm Severity and Count in Ultrawide Field Images and Early Treatment Diabetic Retinopathy Study Photography

Paolo S. Silva et al conducted a single-site comparative study aiming to evaluate the detection of hemorrhage and/or microaneurysm (H/Ma) by ultrawide field (UWF) retinal imaging and standard Early Treatment Diabetic Retinopathy Study (ETDRS) 7-field photographs (ETDRS photos), in 126 eyes of 69 patients with no diabetic retinopathy (DR) or mild or moderate nonproliferative DR (NPDR) as these eyes had the greatest suggested change in DR severity using UWF images.

Retinal H/Ma is among the earliest clinically evident signs of early DR, while its presence and severity have been reliably used to assess the presence, severity, and risk for progression of DR.

The retinal images reviewed in this study, were taken from a previously completed single-site, prospective, clinic-based, comparative-instrument validation trial that had been conducted specifically for the evaluation of the agreement in assessing severity of DR at the retinal lesion level between stereoscopic mydriatic 200° UWF images and mydriatic ETDRS 7-field 35mm slide film photography (ETDRS photos).

A standardized protocol after pupillary dilation at the same visit, provided both UWF imaging (stereoscopic 200° pairs of each eye, acquired using an Optos P200Tx, Optos plc, Dunfermline, Scotland, UK) and ETDRS photos (stereoscopic 35mm color 7-field 30° photography acquired using Zeiss FF4, Carl Zeiss Meditec Inc, Dublin, CA).

There is good to excellent agreement between UWF images and ETDRS photos in determining H/Ma severity, with excellent correlation of H/Ma counts within ETDRS photo fields. UWF peripheral fields identified 49.8% more H/Ma, suggesting a more severe H/Ma in 12.7% of eyes. Given the additional lesions detected in peripheral fields and the known risks associated with H/Ma and peripheral lesions, quantification of H/Ma using UWF images may provide a more accurate representation of DR disease activity and potential greater accuracy in predicting DR progression.

Images were graded for severity and distribution of H/Ma. H/Mas were counted in ETDRS fields 2 to 7 in both ETDRS photos and UWF images. H/Mas were counted in ETDRS fields 2 to 7 in both ETDRS photos and UWF images. H/Mas in the UWF peripheral fields were also counted.

The min outcome measures included kappa (κ) and weighted κ statistics for agreement. Number of H/Ma within and outside ETDRS fields identified in UWF images and ETDRS photos

The results showed that the distribution of DR severity by ETDRS photos was 24 (19.0%) no DR, 48 (38.1%) mild NPDR, and 54 (42.9%) moderate NPDR. A total of 748 of 756 fields (98.9%) were gradable for H/Mas on ETDRS photos and UWF images. Simple κ /weighted κ

statistics for severity of H/Ma: all fields 0.61/0.69, field 2 0.70/0.77, field 3 0.62/0.73, field 4 0.50/0.62, field 5 0.54/0.65, field 6 0.64/0.70, and field 7 0.58/0.63 with overall exact agreement in 81.3% and within 1 step in 97.9% of fields. A greater proportion of fields was graded a more severe H/Ma level in UWF images than in the corresponding ETDRS photos (UWF: 12.7% vs. ETDRS: 6.5%). Evaluating comparable areas in UWF images and ETDRS photos (fields 2–7), a mean of 42.8 H/Mas were identified using ETDRS photos and 48.8 in UWF images ($p = 0.10$). An additional mean of 21.3 H/Mas (49.8% increase, $p < 0.0001$) were identified in the peripheral fields of the UWF images.

Based on the above, the authors concluded that there is good to excellent agreement between UWF images and ETDRS photos in determining H/Ma severity, with excellent correlation of H/Ma counts within ETDRS photo fields. UWF peripheral fields identified 49.8% more H/Ma, suggesting a more severe H/Ma in 12.7% of eyes. Given the additional lesions detected in peripheral fields and the known risks associated with H/Ma and peripheral lesions, quantification of H/Ma using UWF images may provide a more accurate representation of DR disease activity and potential greater accuracy in predicting DR progression.

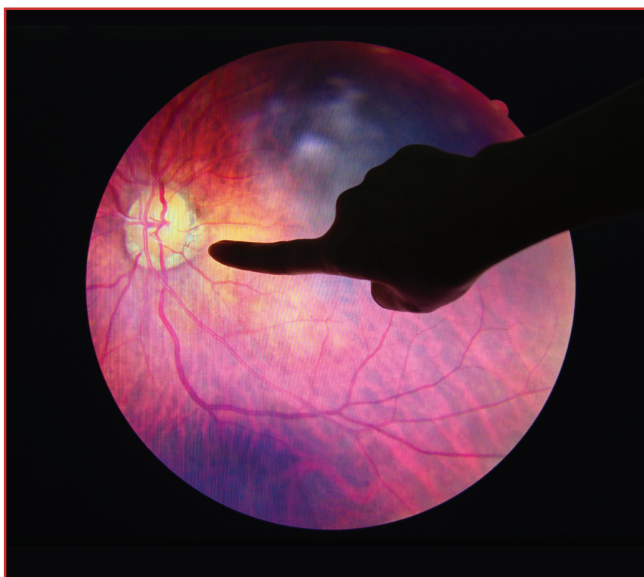
The authors finally commented that “If these findings persist across a broad diabetic population, these noninvasive measures of the posterior and peripheral retina may further improve our ability to identify eyes at risk for retinopathy progression, aiding in monitoring and administration of timely treatment”.

Source: Silva PS, El-Rami H, Barham R, Gupta A, Fleming A, van Hemert J, Cavaillerano JD, Sun JK, Aiello LP. Hemorrhage and/or Microaneurysm Severity and Count in Ultrawide Field Images and Early Treatment Diabetic Retinopathy Study Photography. *Ophthalmology*. 2017 Jul;124(7):970-976. doi: 10.1016/j.ophtha.2017.02.012. Epub 2017 Mar 20.

Incidence and Risk Factors for Developing Diabetic Retinopathy among Youths with Type 1 or Type 2 Diabetes throughout the United States

In this article, Wang SY et al, demonstrated diabetic retinopathy (DR) among young patients with T1DM and T2DM more common than what we thought till now. The authors propose screening young patients with T1DM and T2DM for DR early in the course of the disease since early detection of DR is crucial to the prevention of irreversible damage to the retina and preservation of sight. Thus, the limitation of delays in DR detection will benefit patients by adding to their opportunities for better glycemic control and containment of DR progression.

The authors aimed to identify risk factors for DR in youths with diabetes mellitus, to compare DR rates for youths with type 1 diabetes mellitus (T1DM) and those with T2DM, and to assess whether adherence to DR screening guidelines promoted by the American Academy



of Ophthalmology, American Academy of Pediatrics, and American Diabetes Association adequately capture youths with DR.

Based on the above, the authors performed a retrospective observational longitudinal cohort study.

Youths with T1DM or T2DM exhibit a considerable risk for DR and should undergo regular screenings by eye-care professionals to ensure timely DR diagnosis and limit progression to vision-threatening disease.

Youths aged ≤ 21 years with newly diagnosed T1DM or T2DM who were enrolled in a large US managed-care network were evaluated for DR incidence. The authors sought to (a) identify risk factors for DR development in youths with T1DM and T2DM; (b) investigate whether DM control, as measured by HbA_{1c}, is associated with DR development; and (c) estimate the proportion of youths with each DM type requiring laser or surgical intervention for DR.

Finally, the researchers applied the existing T1DM ophthalmic screening guidelines of the AAO, AAP, and ADA to the youths with T1DM in this data set to assess whether delays in initial DR diagnosis would result.

In this study of youths aged ≤ 21 years with newly diagnosed T1DM or T2DM who were under ophthalmic surveillance, the incidence and timing of DR onset were identified. Kaplan-Meier survival curves assessed the timing of initial diagnosis of DR for participants. Multivariable Cox proportional hazard regression modeling identified factors associated with the hazard of developing DR. Model predictors were age and calendar year at initial diabetes mellitus diagnosis, sex, race/ethnicity, net worth, and glycated hemoglobin A_{1c} fraction (HbA_{1c}).

The main outcome measures were the hazard ratios (HRs) with 95% confidence intervals (CIs) for developing DR.

The results showed that among the 2240 youths with T1DM and 1768 youths with T2DM, 20.1% and 7.2% developed DR over a median follow-up time of 3.2 and 3.1 years, respectively. Survival curves demonstrated that youths with T1DM developed DR faster than youths with T2DM ($p < 0.0001$). For every 1-point increase in HbA_{1c}, the haz-

ard for DR increased by 20% (HR = 1.20; 95% CI 1.06-1.35) and 30% (HR = 1.30; 95% CI 1.08-1.56) among youths with T1DM and T2DM, respectively. Current guidelines suggest that ophthalmic screening begin 3 to 5 years after initial diabetes mellitus diagnosis, at which point in our study, >18% of youths with T1DM had already received ≥ 1 DR diagnosis.

The authors discussed that in this study of youths in a large US managed-care network, >20% of youths with T1DM and 7% with T2DM, with a median of >3 years of follow-up, received a diagnosis of DR. Youth with T1DM had nearly a 3-fold-increased incidence and prevalence of DR compared with youths with T2DM. For each year older a child was at initial DM diagnosis, the risk for developing DR increased among those with T1DM. Among patients with T2DM, children of higher socioeconomic status and females seemed to be protected against DR. With every 1-point increase in HbA_{1c}, the hazard of developing DR was also increased by 20% to 30% among patients with T1DM or T2DM.

The authors concluded that these results highlight that DR may be more common than previously suspected in youths with DM, and youths with poor glycemic control may especially benefit from undergoing screening for DR sooner than the current clinical practice guidelines recommend.

Source: Wang SY, Andrews CA, Herman WH, Gardner TW, Stein JD. Incidence and Risk Factors for Developing Diabetic Retinopathy among Youths with Type 1 or Type 2 Diabetes throughout the United States. *Ophthalmology*. 2017 Apr;124(4):424-430. doi: 10.1016/j.ophtha.2016.10.031. Epub 2016 Nov 30.

Editor's Comments

The newly released ESO guidelines suggest first ophthalmic screening for T1DM at the time of DM diagnosis. This is in accordance with the findings of this retrospective observational study from US, which showed that counter to current guidelines suggesting ophthalmic screening to begin 3 to 5 years after initial diagnosis, at 3 years 20% of youths with T1DM had already received ≥ 1 DR diagnosis.

Prof. Constantinos Karabatsas

Lens Power, Axial Length-to-Corneal Radius Ratio, and Association with Diabetic Retinopathy in the Adult Population with Type 2 Diabetes

In their study aiming to calculate crystalline lens power and to determine the relationship between ocular biometry and diabetic retinopathy (DR) in an adult population with type 2 diabetes mellitus (T2DM), He J et al demonstrated that lens power, axial length-to-corneal radius ratio (AL/CR ratio) ratio, and AL were associated with the presence of any DR and moderate DR.

The authors argued that their findings suggested that globe elongation plays a major role in protecting against DR, with lens power and other refractive components contributing.

Based on the World Health Organization's estimations on the increase of diabetics patients' numbers and the seriousness of its microvascular complications and in particular DR, the authors conducted

this cross-sectional, population-based investigation in patients from the Beixinjing community, Changning district, Shanghai, to assess the relationships of AL/CR ratio and other refractive parameters with DR by measuring ocular biometry and serum biometry in subjects with T2DM, and calculating crystalline lens power using the Bennette Rabbetts formula. They also studied the relationships between crystalline lens power, refractive errors, AL/CR ratio, and AL and DR, adjusting for diabetes duration, serum parameters, and other ocular parameters

Random clustering sampling was used to identify adults with T2DM in the Beixinjing community. Spherical equivalent (SE) was determined by subjective refraction that achieved the best corrected vision. Axial length (AL), corneal power (CP), and anterior chamber depth (ACD) were measured using the IOLMaster. Diabetic retinopathy and diabetic macular edema (DME) were assessed by 2 ophthalmologists according to the international DR classification.

The main outcome measures included crystalline lens power calculation by use of the Bennett-Rabbetts formula. The AL-to-corneal radius ratio (AL/CR ratio) was defined as the axial length divided by the mean corneal radius of curvature.

A total of 4011 eyes of 2057 subjects with T2DM were included in the analysis. In multivariate logistic models adjusting for age, sex, duration of diabetes, glycosylated hemoglobin A1c, serum creatinine, body mass index, systolic blood pressure, and cataract, after categorizing values into quartiles, there were trend associations between lens power and any DR ($p = 0.01$), between AL/CR ratio and any DR ($p = 0.02$), and between AL and any DR ($p = 0.03$), between lens power and moderate DR ($p = 0.02$), and between AL and moderate DR ($p = 0.02$); eyes with higher AL/CR ratio were less likely to have any DR (odds ratio [OR], 0.43; 95% confidence interval [CI], 0.24-0.78; $p = 0.01$ per 1 increase) and moderate DR (OR, 0.44; 95% CI, 0.21-0.93; $p = 0.03$ per 1 increase), eyes with longer AL were less likely to have any DR (OR, 0.88; 95% CI, 0.81-0.95; $p = 0.002$ per millimeter increase) or moderate DR (OR, 0.89; 95% CI, 0.80-0.98; $p = 0.02$ per millimeter increase), and eyes with higher SE were more likely to have any DR (OR, 1.08; 95% CI, 1.03-1.13; $p = 0.003$ per diopter increase).

Therefore, the authors concluded that in persons with T2DM, lens power, AL/CR ratio, and AL were associated with the presence of any DR and moderate DR.

The authors concluded the article noting that "These findings contribute further insights into the pathogenetic pathways of DR. In addition, clinicians should pay greater attention to the state of lens power, AL/CR ratio, and refractive error in patients with T2DM".

Source: He J, Xu X, Zhu J, Zhu B, Zhang B, Lu L, He X, Bai X, Xu X, Zou H. Lens Power, Axial Length-to-Corneal Radius Ratio, and Association with Diabetic Retinopathy in the Adult Population with Type 2 Diabetes Ophthalmology. 2017 Mar;124(3):326-335. doi: 10.1016/j.opht.2016.10.041. Epub 2016 Dec 16.

Editor's Comments

This is a population based cohort study that addresses the relationship between DR and lens power in patients with T2DM.

The study suggests a protective effect.

Several studies and meta analysis reviews also suggested that individuals with myopia appear to have a reduced risk of severe DR.

The practical implications for these studies will depend on how much we understand the exact mechanism of this effect and to what extent this knowledge can be used to prevent and treat DR more effectively

Dr. Omar Al Jabri

Diabetic Retinopathy Screening Using Deep Neural Network

In their study Ramachandran N et al pointed out that with the global burden of diabetes mellitus and hence diabetic retinopathy (DR) projected to increase, there will be a growing demand for DR screening services in a world with limited resources. They noted the burgeoning interest in the use of deep neural network in diabetic retinal screening.

The aim of this study was to assess whether a deep neural network could satisfactorily select patients enrolled in the ODEMS, who need to be seen by an ophthalmologist in clinic due to the severity of their DR or diabetic macular edema (DME). For comparison to international data, the authors also assessed the deep neural network's ability to satisfactorily grade referable DR and DME from the publicly available international Messidor database.

Diabetic retinal photos from Otago database photographed during October 2016 (485 photos), and 1200 photos from Messidor international database were include in this retrospective audit.

This retrospective study which took place in April 2017 and looked at diabetic retinal screening photos from 1 October 2016 to 31 October 2016 from ODEMS as well as the 1200 diabetic retinal photos from Messidor comprised a receiver operating characteristic curve to illustrate the ability of a deep neural network to identify referable diabetic retinopathy (moderate or worse diabetic retinopathy or exudates within one disc diameter of the fovea).

The investigator (NR) collected and selected best quality posterior pole photos that were graded during October 2016 from ODEMS and uploaded these onto Visiona, along with posterior pole Messidor photos for grading. Statistical analysis was carried out using 'IBM SPSS statistics 24'. ROC curve was plotted to test DR score from Visiona against referable criteria for both ODEMS and Messidor.

The main outcome measures were area under the receiver operating characteristic curve, sensitivity and specificity.

Results showed that for detecting referable diabetic retinopathy, the deep neural network had an area under receiver operating characteristic curve of 0.901 (95% confidence interval 0.807-0.995), with 84.6% sensitivity and 79.7% specificity for Otago and 0.980 (95% confidence interval 0.973-0.986), with 96.0% sensitivity and 90.0% specificity for Messidor.

The authors conclude that their study showed that a deep neural network can detect referable diabetic retinopathy with sensitivities and specificities close to or better than 80% from both an international and a domestic (New Zealand) database. They expressed the belief that deep neural networks can be integrated into community screening once they can successfully detect both diabetic retinopathy and diabetic macular edema.

These results demonstrated that a deep neural network can successfully detect referable DR with high areas under the ROC curves for both a domestic (ODEMS) and international database (Messidor). The area under the ROC curve with ODEMS images was 0.901 (95% confidence interval [CI], 0.807–0.995), while the area under the ROC curve for the Messidor was 0.980 (95% CI 0.973–0.986). The wider CI for the ODEMS is explained by the smaller proportion of referable DR and the smaller sample size compared with Messidor. There was no statistically significant difference at $p < 0.05$ between the areas under the two ROC curves.

The best combination of sensitivities and specificities with ODEMS (84.6% sensitivity, 79.7% specificity) and Messidor (96.0% sensitivity, 90.0% specificity) were at DR score cut-off values 0.55 and 1.89, respectively.

Source: Ramachandran N, Hong SC, Sime MJ, Wilson GA. Diabetic Retinopathy Screening Using Deep Neural Network. *Clin Exp Ophthalmol*. 2017 Sep 7. doi: 10.1111/ceo.13056. [Epub ahead of print]

Editor's Comments

It is worthwhile to consider use of artificial intelligence of deep neural network to detect referable diabetic retinopathy. The use of artificial intelligence in a nationally screening program would eliminate inter-rater and intra-rater variability, with a reliable confidence interval and high sensitivity and specificity of more than 80%.

Dr. Wadeia Mohammad Al Sharief

The United Kingdom Diabetic Retinopathy Electronic Medical Record Users Group: Report 3: Baseline Retinopathy and Clinical Features Predict Progression of Diabetic Retinopathy

Lee CS et al demonstrated that baseline diabetic retinopathy severities and clinical features of initial diabetic retinopathy screening remain key prognostic factors. The EMR-facilitated feature-based evaluations of diabetic retinopathy provide not only a large cohort of patients for epidemiologic study but also the basis for large clinical studies in which important outcome predictors can be assessed.

The authors performed this multicenter, national cohort study to determine the time and risk factors for developing proliferative diabetic retinopathy (PDR) and vitreous hemorrhage (VH).

To this end, anonymized data of 50 254 patient eyes with diabetes mellitus at 19 UK hospital eye services were extracted at the initial and follow-up visits between 2007 and 2014. Time to progression of PDR and VH were calculated with Cox regression after stratifying by baseline diabetic retinopathy (DR) severity and adjusting for age, sex, race, and starting visual acuity.

Results showed that progression to PDR in 5 years differed by baseline DR: no DR (2.2%), mild (13.0%), moderate (27.2%), severe nonproliferative diabetic retinopathy (NPDR) (45.5%). Similarly, 5-year progression to VH varied by baseline DR: no DR (1.1%), mild (2.9%), moderate (7.3%), severe NPDR (9.8%). Compared with no DR, the patient eyes that

presented with mild, moderate, and severe NPDR were 6.71, 14.80, and 28.19 times more likely to develop PDR, respectively. In comparison to no DR, the eyes with mild, moderate, and severe NPDR were 2.56, 5.60, and 7.29 times more likely to develop VH, respectively. In severe NPDR, the eyes with intraretinal microvascular abnormalities (IRMA) had a significantly increased hazard ratio (HR) of developing PDR (HR 1.77, 95% confidence interval [CI] 1.25–2.49, $p = .0013$) compared with those with venous beading, whereas those with 4-quadrant dot-blot hemorrhages (4Q DBH) had 3.84 higher HR of developing VH (95% CI 1.39–10.62, $p = .0095$).

The authors concluded that baseline severities and features of initial DR are prognostic for PDR development. IRMA increases risk of PDR whereas 4Q DBH increases risk of VH.

They emphasized “Proliferative diabetic retinopathy and vitreous hemorrhage are important endpoints of sight-threatening diabetic retinopathy. Our study demonstrates that baseline diabetic retinopathy severities and clinical features of initial diabetic retinopathy screening remain key prognostic factors. The EMR-facilitated feature-based evaluations of diabetic retinopathy provide not only a large cohort of patients for epidemiologic study but also the basis for large clinical studies in which important outcome predictors can be assessed.”

Source: Lee CS, Lee AY, Baughman D, Sim D, Akelere T, Brand C, Crabb DP, Denniston AK, Downey L, Fitt A, Khan R, Mahmood S, Mandal K, McKibbin M, Menon G, Lobo A, Kumar BV, Natha S, Varma A, Wilkinson E, Mitry D, Bailey C, Chakravarthy U, Tufail A, Egan C; UK DR EMR Users Group. The United Kingdom Diabetic Retinopathy Electronic Medical Record Users Group: Report 3: Baseline Retinopathy and Clinical Features Predict Progression of Diabetic Retinopathy. *Am J Ophthalmol*. 2017 Aug;180:64–71. doi: 10.1016/j.ajo.2017.05.020. Epub 2017 May 29.

Editor's Comments

Study design, methodology and statistical analysis looks strong, with big sample size.

Dr. Nahed Monsef

Screening Intervals for Diabetic Retinopathy and Implications for Care

Scanlon PH introduces his study by making the point that life expectancy has doubled around the world. This increase is true even in countries with lower levels of life expectancy, where life expectancy has nearly doubled during the last two centuries.

This increased life expectancy has led to a change in the nature of the diseases being treated. With the increase of the older population, there are higher numbers of patients with chronic diseases such as diabetes and cancer. Furthermore, the widely discussed epidemic of diabetes has consequently led to an epidemic of diabetic retinopathy (DR). This, has given rise to the need for DR screening programs, and such have been set up around the world with a tendency of greater success in countries with state-run nationalized health systems.

The purpose of this study was to review the evidence that lower risk groups who could safely be screened less frequently for sight-threatening diabetic retinopathy (DR) than annually.

Dr Scanlon reminds us that data have demonstrated that people with no DR in either eye are at a low risk of progression to sight-threat-

ening DR over a 2-year period (event rate 4.8 per 1000 person years), irrespective of whether the screening method is one-field non-mydratic or two-field mydratic digital photography. Low risk has been defined as no retinopathy on two consecutive screening episodes or no retinopathy on one screening episode combined with risk factor data. The risk of an extension to 2 years is less than 5 per 1000 person years in a population with a national screening program, and the general standard of diabetes care is relatively good, whether low risk is defined as no retinopathy on two consecutive screening episodes or no retinopathy on one screening episode combined with other risk factor data. The definition used in different populations is likely to depend on the availability of data.

The author concluded that the data from real-world screening program has demonstrated that people with diabetes who have no DR in either eye are at the low risk of progression to referable or sight-threatening DR over a 2-year period (event rate 4.8 per 1000 person years).

Low event rates appear to be irrespective of whether the diagnosis of no DR is based on one-field non-mydratic photography as is used in the protocol in Scotland or northern Spain or whether it is based on 2-field mydratic digital photography as is used in other UK countries and Sweden.

Source: Scanlon PH. Screening Intervals for Diabetic Retinopathy and Implications for Care. *Curr Diab Rep.* 2017 Sep 5;17(10):96. doi: 10.1007/s11892-017-0928-6.

Editor's Comments

Diabetes mellitus is a global disease with a high prevalence in our area, UAE now ranks as number 15th worldwide with prevalence of dm, screening every one year will be more informative & help early discovering of dr & hence interfering in proper time that save patient vision & decrease burden on government for treating complications

Dr. Mohamed Abdul Nabi

Diabetic Eye Screening: Knowledge and Perspectives from Providers and Patients

Despite 90% of blindness being preventable through screening and treatment, diabetic retinopathy remains the leading cause of blindness among working-age US adults. Sadly though, fewer than 50% of people with diabetes in the USA follow diabetic eye screening guidelines. Liu et al summarized current knowledge and perspectives to better understand why diabetic eye screening rates remain low and future directions towards preventing blindness from diabetes. The authors introduce their study by stressing that diabetic retinopathy affects a staggering 126.6 million people worldwide and is expected to increase rapidly with the continued rise in the diabetes population.

Significant advancements in the past 10 years include primary care and patient-oriented interventions as well as the use of teleophthalmology. In England for example, the implementation of a national teleophthalmology program for diabetic retinopathy resulted in diabetic eye disease not being anymore the first cause of certifiable blindness. Teleophthalmology offers an evidence-based form of diabetic eye screening that increases patient access and adherence. This

form of screening offers high-quality, cost-effective eye care and often can be performed without pupil dilation. Furthermore, it is possible to integrate patient education into teleophthalmology programs, for example, by providing patient educational materials or education at the time of retinal imaging.

Primary care providers have adequate knowledge and awareness of diabetic eye screening guidelines, but encounter barriers to ensuring patients obtain screening due to the high burden and complexity of tasks they are required to complete during an average 15–20 min patient clinic visit as well as lack of access to patients' eye exam records.

Eye care providers face rapidly growing demands for diabetic eye screening, with an increasing shortage of eye care providers worldwide.

Multiple workflow and systems-level barriers affect providers. Patient barriers include a limited understanding of screening and lack of access to care. Interventions have been developed, but new barriers exist towards sustaining their impact. More research is needed to identify and implement the best practices to increase diabetic eye screening rates long-term.

A support for less frequent screening of patients with no or minimal diabetic retinopathy has been expressed in publications, including that of the Diabetes Complications and Control Trial/Epidemiology of Diabetes Interventions and Complications (DCCT/EDIC). Still, there are those who support that highly tailored screening algorithms may be too complex for effective implementations. Furthermore, the expanding role of anti-vascular endothelial growth factor (anti-VEGF) agents in the treatment of early may be a countervailing force supporting more frequent screening.

To make things more complicated, Liu et al hold that "Changes to guidelines regarding the recommended frequency of retinopathy screening could cause confusion among patients and providers, potentially worsening screening rates if effective decision-support systems are not well established. Thus, there is a growing need for proactive care coordination and communication between primary care and eye care providers, which has been shown to facilitate diabetic eye screening."

Source: Liu Y, Swearingen R. Diabetic Eye Screening: Knowledge and Perspectives from Providers and Patients. *Curr Diab Rep.* 2017 Aug 31;17(10):94. doi: 10.1007/s11892-017-0911-2.

Editor's Comments

"Identifying barriers to diabetic screening help us to optimise our implementation of the screening programs in order to reach our ultimate goal of bringing down the rate of diabetes-induced blindness to the lowest level possible"

Mohamed A. Awadalla

Crowdsourcing and Automated Retinal Image Analysis for Diabetic Retinopathy

Mudie LI et al familiarize the reader with crowdsourcing, the novel method for processing information and generating data that is gaining popularity for its cost-effectiveness and fast results in speeding up the process of grading images as well as further reducing costs of screening for diabetic retinopathy (DR).

The authors note that as the number of people with diabetic reti-

nopathy (DR) in the USA is expected to increase threefold by 2050, the need to reduce health care costs associated with screening for this treatable disease is ever present. Crowdsourcing and automated retinal image analysis (ARIA) are two areas where new technology has been applied to reduce costs in screening for DR.

Crowdsourcing has high sensitivity for normal vs abnormal images; however, when multiple categories for severity of DR are added, specificity is reduced. ARIAs have higher sensitivity and specificity, and some commercial ARIA programs are already in use. Deep learning enhanced ARIAs appear to offer even more improvement in ARIA grading accuracy. The utilization of crowdsourcing and ARIAs may be a key to reducing the time and cost burden of processing images from DR screening.

Liu et al conclude their article by explaining that rapid and accurate grading of images is a key for successful DR screening and thus it is a logical progression for technology to be applied to further streamline and reduce costs of grading images. Crowdsourcing has been used grade fundus images for DR with high sensitivity for normal vs abnormal. As would be expected, the accuracy of grading seems to decrease when categories for level of severity of DR are added. There is some evidence to suggest that grading can be improved with the addition of brief training prior to completion of the task. The field of crowdsourcing for DR is still evolving with different techniques being trialed to improve the information generated, such as localizing pathology with annotation and using real-time feedback and interaction among workers.

ARIAs are capable of grading images for DR with high sensitivity and specificity, the authors wrote. So much so that there are now ARIAs in use in screening programs around the globe. Of note, one study suggested that ARIAs perform similarly whether used as a first pass to reduce burden on human grading or as a replacement to human grading, with the latter being more cost-effective in saving over USD \$100,000 to screen approximately 20,000 individuals. ARIAs have also evolved with the new literature reporting improved sensitivities and specificities of ARIAs with deep learning enhancement. Moving forward, there may be opportunities for convergence of crowdsourcing and deep learning methods.

Source: Mudie LI, Wang X, Friedman DS, Brady CJ. Crowdsourcing and Automated Retinal Image Analysis for Diabetic Retinopathy. *Curr Diab Rep*. 2017 Sep 23;17(11):106. doi: 10.1007/s11892-017-0940-x.

Determining Diabetic Retinopathy Screening Interval Based on Time from No Retinopathy to Laser Therapy

Hughes et al concluded their review by saying that “analysis of screening intervals should be based on time to laser therapy in the screened population. This indicates lower rates of laser treatment than inferred from analysis of sight-threatening retinopathy (STR) determined photographically, which overestimates the incidence of disease needing treatment. For all patients with no retinopathy, a change to follow-up screening at two to three years results in almost zero delay in treatment. Patients with no or non-proliferative retinopathy undergoing regular screening and treatment when indicated now have a very low risk of blindness from diabetes when assessed in long-term follow-up.”

The authors performed this analysis aiming to determine the necessary screening interval for retinopathy in diabetic patients with no retinopathy based on time to laser therapy. Further, they aspired to assess long-term visual outcome following screening.

This was a cohort study of ophthalmologic outcomes in unselected diabetic patients attending a community screening program in 2001/2002. The study was performed in a population-based community screening program in North Wales, 2917 patients were followed until death or for approximately 12 years. At screening, 2493 had no retinopathy; 424 had mostly minor degrees of non-proliferative retinopathy. Data on timing of first laser therapy and visual outcome following screening were obtained from local hospitals and ophthalmology units.

Survival analysis showed that very few of the no retinopathy at screening group required laser therapy in the early years compared with the non-proliferative retinopathy group ($p < 0.001$). After two years, <0.1% of the no retinopathy at screening group required laser therapy, and at three years 0.2% (cumulative), lower rates of treatment than have been suggested by analyses of sight-threatening retinopathy determined photographically. At follow-up (mean 7.8 ± 4.6 years), mild to moderate visual impairment in one or both eyes due to diabetic retinopathy was more common in those with retinopathy at screening (26% vs. 5%, $p < 0.001$), but blindness due to diabetes occurred in only 1 in 1000.

The authors concluded that the optimum screening intervals should be determined from time to active treatment. Based on requirement for laser therapy, the screening interval for diabetic patients with no retinopathy can be extended to two to three years. Patients who attend for retinal screening and treatment who have no or non-proliferative retinopathy now have a very low risk of eventual blindness from diabetes.

Source: Hughes D, Nair S, Harvey JN. Determining Diabetic Retinopathy Screening Interval Based on Time from No Retinopathy to Laser Therapy. *J Med Screen*. 2017 Dec;24(4):170-175. doi: 10.1177/0969141316672687. Epub 2016 Nov 3.

Editor's Comments

This article shows confirmation about most patients with no DR at initial screening doing fine after 5 years for type 1 diabetes and after 2 years for type 2.

It is interesting that the levels of HbA1c and history of hypertension were a strong predictor for the need for treatment in the future.

I think that pairing HbA1c and history of hypertension with findings at initial screening can guarantee that a longer screening follow up will not be detrimental for our patients.

Although our screening program is a young one, which has been running for a little longer than 2 years by now, it would be interesting to review our data to ascertain if our subset of population adjust with published results.

We are also awaiting DRCRnet protocol V findings as it could be a game changer should it prove that patients with center-involving macular edema and VA 20/25 or better would benefit from early treatment

Dr. Patricio M. Aduriz-Lorenzo

Diabetic Retinopathy Screening Guideline UAE

Table Of Contents

Table of content 14	Diabetic Retinopathy Screening 19
Preface 14	Diabetic Retinopathy Diagnostic Approach 21
Acknowledgement 14	Diabetic Retinopathy Management 23
Summary 15	Diabetic Retinopathy Referral Guide 24
Glossary 16	Diabetic Retinopathy Screening Guide in Primary Health Care 25
Introduction 17	References 26

Preface

Diabetic retinopathy (DR) and associated macular edema is a preventable cause of VA dysfunction and blindness. Through a continuous DR screening program most of the complications can be prevented and/or reversed. Our societies have teamed up to bring to you this updated screening guidelines in an effort to develop a unified program for UAE. Our objective is to reduce preventable blindness and improve vision

quality for our diabetic population. I would like to thank all the contributors for their work and support to reach a nationwide agreement and successful consensus.

Patricio M. Aduriz-Lorenzo
Chair of the Committee

Acknowledgement

The following consensus committee members contributed to the development of the guidelines:

Chair: Dr. Patricio M. Aduriz-Lorenzo MD. DO. FRCSEd. FRCSEd. FEBO. HOD Ophthalmology & Consultant Medical Retina. Dubai Hospital, DHA. ESO.
Co-Chair: Dr. Mohamed Awadalla MD, FRCSEd, Professor of Ophthalmology, Cairo University, Egypt. Consultant Ophthalmology & VR Surgeon, MOHAP, UAE
Dr. Abdulrazzaq Al Madani, Consultant Endocrinologist, Al Borj Medical Centre
Dr. Ayesha Mohammad Sultan AlOlama, Specialist Senior Registrar, Health Affairs Department, PHCSS
Dr. Buthaina Bin Belaila, Consultant family physician, Head of Non Communicable Disease, Ministry Of Health & Prevention
Dr. Fatheya Al Awadi Head of Endocrine Department - Dubai Hospital
Chairperson – Diabetes Combat and Control Committee - DHA
Dr. Fatma Al Amiri, Al Qassimi Hospital, MOH
Dr. Hanan Ali Mubarak Obaid, Consultant and Head of Acute & Chronic Diseases Unit, Health Affairs Department, PHCSS.
Dr. Konstantinos Karabatsas MD, DM, FRCSEd, As.Professor of Ophthalmology, Athens University of Applied Sciences, Consultant Ophthalmic Surgeon, LaserVision.gr, Athens, Greece
Ms. Mai Haider Awadalla, Charge Nurse, Health Affairs Department, PHCSS.

Dr. Manal Taryam, Consultant ophthalmologist, CEO PHCSS
Dr. Mohamed Abdul Nabi, Consultant Ophthalmologist and Head of Retina & Cataract Surgery Mafraq Hospital, Abu Dhabi,UAE
Dr. Mohamed Ibrahim ElDisouky, Specialist Registrar, Health Affairs Department, PHCSS.
Dr. Mohammed Al Amri MBBS, MD, HSDO, Medical Retina Specialist, consultant Ophthalmologist, President of Gulf Retina group (GRG)
Vice President of QOIC and Head of Scientific Committee, Member of National Committee for the Right to Sight, Adjunct professor in Medical College of Sharjah University Head of ophthalmic CME in Al Qassimi hospital.
Dr. Moulham Ashtar, Head of Clinical Effectiveness Office, Health Affairs Department, PHCSS
Dr. Nabeyon Taha Faeq, Member of General Medical Committee & Specialist Senior Registrar, Health Centers Department, PHCSS
Dr. Nahed AbdulKhaleq, Monsef Consultant Family Medicine RCGP Fellowship, ABFM, MSc Health Care Management Director of Health Affairs Department Primary Health care Services Sector Dubai Health Authority
Dr. Omar Naseeb Al Jabri, Chief Medical Officer Ambulatory Health-care Services Abu Dhabi Health Services Company (SEHA)
Dr. Saleh Al Messabi, President of the Emirates Society of Ophthalmology
Dr. Wadeia Mohammad Al Sharief, Consultant Family Physician, President Emirates Family Medicine Society, EMA, Dubai Health Authority

Summary

A series of three meetings aiming for the development of a consensus on screening of Diabetic Retinopathy took place in Dubai, with the support of the Emirates Society of Ophthalmology, the Emirates Diabetes Society, the Emirates Family Medicine Society and the National Emirates Committee for right and sight.

The consensus meetings were chaired by Drs Patricio M. Aduriz-Lorenzo (ESO, DHA) and Mohamed Awadalla (ESO, MOH) and the initial screening guidelines were approved by unanimous consent among all committee members.

The objectives of the guidelines are to empower physicians to help reduce preventable blindness and improve vision and life quality for diabetic patients. Diabetic retinopathy represents 4.8% of the total cases of blindness globally. United Arab Emirates (UAE) is ranked 16th worldwide, with the prevalence of diabetic retinopathy reaching about 19%.

The Guidelines are well written, concise and simplified, so as to be adapted relatively easy by interested parts. They cover Screening, Diagnostic Approach, Management, Referral Guides for Diabetic Retinopathy and Diabetic Retinopathy Screening Guide in Primary Healthcare. The guidelines are mainly based on the AAO guidelines, but they also incorporate points from other countries guidelines, adapted to local conditions. They are already in use in Dubai and the system there seems to operate well, with a number of fundus cameras available in primary care services.

These guidelines answer the 3 main questions: Who should be screened, when and where.

In brief, the recommendations adopted as regards patients in need of screening, are as follows:

1. In type 1 diabetes patients, baseline screening (at diagnosis) and then re-screen at 5 years. Thereafter, yearly exam.
2. In type 2 diabetics, baseline screening (at diagnosis) and yearly exam thereafter.
3. Pregnant women with pre-existing diabetes, preconception screening and at pregnancy confirmation, ideally within the 1st month of pregnancy. Follow-up every 3 to 12 months thereafter for patients with none to moderate retinopathy, and every 1 to 3 months for patients with severe or worse retinopathy.
4. All patients who are screened should also undergo Visual Acuity recording, with or without glasses and best corrected acuity with glasses or with pin hole.

Screening should be performed at PHCs by trained and certified nurses mainly, but sometimes by doctors as well. Digital fundus photography is the preferred method for screening, and for this purpose, digital cameras are already in operation and the network is planned to be expanded. Telemedicine technology in Retina Camera screening for Diabetic Patients is the first project of its kind in the UAE and the region. As mentioned "This innovative idea will utilize the use of retinal cameras in **all primary health care centers** to have **retinal photos of Diabetic patients** and after initial screening **send those images electronically** to a **reference center** for secondary evaluation if needed."

The guidelines are completed by the Diabetic Retinopathy Referral Guide for family physicians and the Diabetic Retinopathy Screening Guide in Primary Healthcare.

I would strongly encourage all physicians and healthcare workers involved in the diabetic patients care in the UAE region, to get familiar with these guidelines. For full information, please read forward.

Glossary

Below are definitions that are used in diabetic retinopathy:

- **Microaneurysms (MA):** The earliest clinical sign of diabetic retinopathy; these occur secondary to capillary wall outpouching due to pericyte loss; they appear as small, red dots in the superficial retinal layers.
- **Dot and blot hemorrhages** Appear similar to microaneurysms if they are small; they occur as microaneurysms rupture in the deeper layers of the retina, such as the inner nuclear and outer plexiform layers.
- **Flame-shaped hemorrhages:** Splinter hemorrhages that occur in the more superficial nerve fiber layer.
- **Cotton-wool spots (CWS)** Nerve fiber layer infarctions from occlusion of precapillary arterioles; they are frequently bordered by microaneurysms and vascular hyperpermeability.
- **Venous loops and venous beading (VB):** Frequently occur adjacent to areas of nonperfusion; they reflect increasing retinal ischemia, and their occurrence is the most significant predictor of progression to proliferative diabetic retinopathy (PDR).
- **Intraretinal microvascular abnormalities (IRMA):** Remodeled capillary beds without proliferative changes; can usually be found on the borders of the nonperfused retina
- **Anti-vascular endothelial growth factor (VEGF):** Substances that inhibit the action of vascular endothelial growth factor protein.
- **Clinically significant macular edema (CSME):** Retinal thickening at or within 500 µm of the center of the macula; and/or hard exudates at or within 500 µm of the center of the macula, if associated with thickening of the adjacent retina; and/or a zone or zones of retinal thickening one disc area in size, any part of which is within one disc diameter of the center of the macula.
- **Early Treatment Diabetic Retinopathy Study (ETDRS):** A study that investigated the value of photocoagulation surgery for patients with NPDR or PDR who did not have high-risk characteristics.
- **Focal photocoagulation:** A laser technique directed to abnormal blood vessels with specific areas of focal leakage (i.e., microaneurysms) to reduce chronic fluid leakage in patients with macular edema.
- **Grid photocoagulation:** A laser technique in which a grid pattern of scatter burns is applied in areas of diffuse macular edema and nonperfusion. Typically, fluorescein angiograms of these areas show a diffuse pattern rather than focal leakage
- **Macular edema:** Thickening of the retina within one or two disc diameters of the center of the macula. (See Clinically significant macular edema.) Any other thickening of the macula not within this area is non-CSME.
- **Mild nonproliferative diabetic retinopathy (NPDR):** At least one microaneurysm and less than moderate nonproliferative diabetic retinopathy.
- **Moderate nonproliferative diabetic retinopathy (NPDR):** Hemorrhages and/or microaneurysms greater than standard photograph 2A, and/or soft exudates, venous beading, or intraretinal microvascular abnormalities present but less than severe nonproliferative retinopathy.
- **Severe nonproliferative diabetic retinopathy (NPDR):** Using the 4-2-1 rule, the presence of at least one of the following features: (1) severe intraretinal hemorrhages and microaneurysms, equaling or exceeding standard photograph 2A, present in four quadrants; (2) venous beading in two or more quadrants (standard photograph 6A); or (3) moderate intraretinal microvascular abnormalities equaling or exceeding standard photograph 8A in one or more quadrants
- **New vessels at the optic disc (NVD):** New vessels at the optic disc; neovascularization on or within one disc diameter of the optic disc.
- **New vessels elsewhere in the retina (NVE):** New vessels elsewhere in the retina; neovascularization elsewhere in the retina and greater than one disc diameter from the optic disc margin.
- **New vessels on the iris (NVI):** New vessels on the iris; neovascularization of the iris.
- **Nonproliferative diabetic retinopathy (NPDR):** The phases of diabetic retinopathy with no evidence of retinal neovascularization.
- **Optical coherence tomography (OCT):** A diagnostic test using low energy lasers that takes a cross-section image of the retina, Used mostly to determine if there are membranes on the surface of the macula or fluid within or beneath it.
- **Panretinal photocoagulation:** A type of laser surgery used for patients with proliferative diabetic retinopathy. The surgery is delivered in a scatter pattern throughout the peripheral fundus and is intended to lead to a regression of neovascularization.
- **Retinal hard exudate:** Protein and lipid accumulation within the retina.
- **VTDR:** Vision-threatening diabetic retinopathy.
- **Wisconsin Epidemiologic Study of Diabetic Retinopathy:** A large epidemiologic study of complications associated with diabetes and of risk factors associated with those complications

Introduction

Diabetic retinopathy is the retinal consequence of chronic progressive diabetic microvascular leakage and occlusion. It eventually occurs to some degree in all patients with diabetes mellitus.[1]

There are two types:

- Non-proliferative diabetic retinopathy (NPDR) is the early stage of the disease and is less severe. Blood vessels in the eye may leak fluid into the retina, which leads to blurred vision.[1]
- Proliferative diabetic retinopathy (PDR) is the more advanced form of the disease. New blood vessels start to grow in the eye (neovascularisation), which are fragile and can haemorrhage. This may cause vision loss and scarring of the retina.[1]

Epidemiology:

In patients with type 1 diabetes mellitus, retinopathy is rare before puberty and rare in patients who have had diabetes for <7 years.[2] Approximately 25% patients with type 2 diabetes have retinopathy at diagnosis, presumably as a consequence of unrecognised disease.[3]

Prevalence in patients <30 years of age at the time of diagnosis has been reported to be 17% in those who had diabetes (type 1 and 2) for <5 years and 98% in those who had diabetes for >15 years.[2] Prevalence in patients >30 years of age at time of diagnosis was 29% and 78% for those who had diabetes <5 years and >15 years, respectively.[3] The 10-year incidence of retinopathy, progression of retinopathy, and progression to proliferative retinopathy was highest in the group diagnosed before 30 years of age, intermediate in the insulin-taking group diagnosed at ≥30 years of age, and lowest in the non-insulin-taking group diagnosed at ≥30 years of age.[4]

Although differences in incidence by ethnic group have been demonstrated, even when systemic risk factors are controlled it is difficult to determine whether these differences arise from ethnic

variation in the genome or from factors such as variations in the access and cost of care.[5] [6] Globally, there is expected to be an increase in the burden of retinopathy related to the increase in the incidence of diabetes. This was estimated at 3% in 2000 and is expected to increase to at least 4% by 2030 because of the projected increases in incidence of obesity and longevity.[7]

Diabetic retinopathy represents 4.8% of the total cases of blindness globally and this amounted to 37 million people worldwide and according to statistics from the International Agency for Prevention of Blindness in 2013 it affects 77% of people with diabetes.[8]

United Arab Emirates (UAE) is ranked 16th worldwide, with 19.3% of the UAE population living with diabetes [9], in which the prevalence of diabetic retinopathy is reaching to 19% in UAE.[10]

Aetiology:

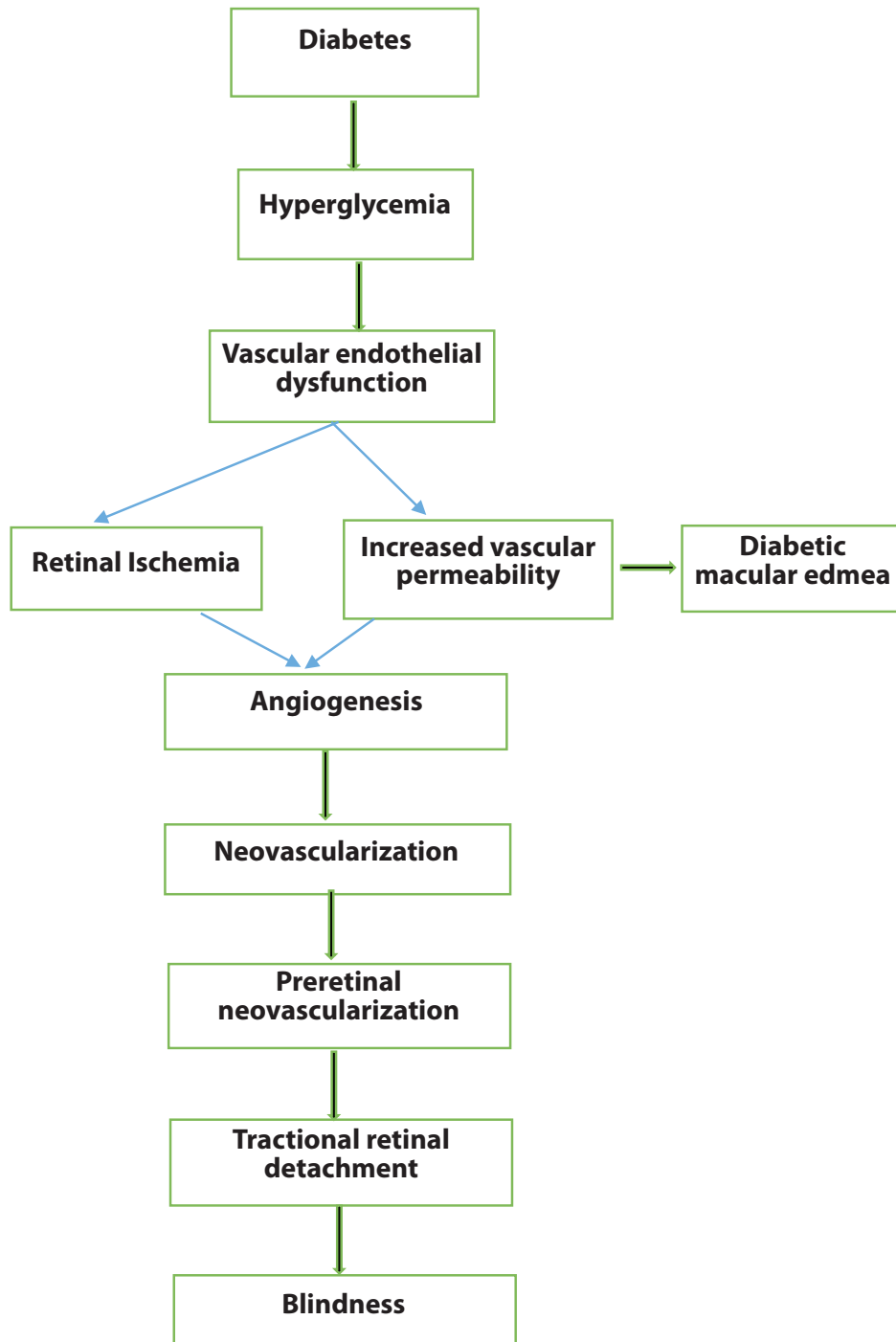
Many hypotheses consider hyperglycaemia to be the principal aetiological factor in diabetic retinopathy, because hyperglycaemia causes changes in:

- Blood composition, including increased viscosity, reduced white cell deformability, and changes in procoagulant, anti-fibrinolytic, and platelet aggregation activity.[11] [12] [13]
- Blood vessel walls, including loss of the normally anti-thrombogenic nature of the endothelial lining.[14]
- Blood flow as a result of microthrombus formation, vascular occlusion, and impairment of retinal autoregulation.[15]

These changes result in retinal capillary leakage and non-perfusion, which causes tissue hypoxia and may precipitate alterations in non-vascular retinal tissue.

Hypertension and genetic factors (suggested by the familial clustering of severe diabetic retinopathy) are also considered aetiological factors.[15] [16]

Pathophysiology: [10]



Risk factors: [1]

- Young-onset diabetes
- Longer duration of diabetes
- Poor glycaemic control
- Hypertension
- Renal disease
- Ethnic groups
- Pregnancy
- Cataract surgery
- Elevated lipid levels

Diabetic Retinopathy Screening

Screening for retinopathy is reported to be cost-effective.[17] The condition can progress to a sight-threatening stage with few symptoms.[18] Although effective treatments exist, they are more effective at preventing than at reversing visual loss.[19] [20] Clinical outcomes are improved if intervention is undertaken early.[21]

The American Academy of Ophthalmology recommends screening for retinopathy as follows:[22]

- **In type 1 diabetes:** Baseline screening at the time of diagnosis, then re-screen at 5 years and yearly thereafter.
- **In type 2 diabetes:** at time of diagnosis of diabetes, with yearly follow-up.
- **In pregnancy with pre-existing diabetes:** prior to conception and as soon as pregnancy is confirmed (ideally within the 1st month of pregnancy) with follow-up every 3 to 12 months for none, mild, and moderate retinopathy, and 1 to 3 months for severe or worse retinopathy.
- **Patients with Gestational diabetes** don't require screening for diabetic retinopathy.[22]
- **Visual Acuity Checkup:** All patients attending screening should have VA recorded with or without glasses and BCVA or VA with pin hole.

Digital fundus photography is the preferred method of screening because it provides a permanent record for quality assurance and audit.[23]

Digital fundus photography using telemedicine technology in retinal Camera Screening for Diabetic Patients is considered the first project of its kind in the UAE and the region for early diagnosis of retinopathy in diabetic patients, and this project was adopted by DHA in line with Dubai Government strategy (regarding the quality and availability of health care services) and the smart government.

This innovative idea will utilize the use of retinal cameras in **all primary health care centers** to have **retinal photos of Diabetic patients** and **send those images electronically** to the **retinal team in Dubai hospital** for secondary evaluation if needed.

The challenge that exists today in many countries is to reach the whole population with adequate health care services and to ensure their utilization. According to the World Health Report 2008, Primary Health Care, now more than ever, health systems in developing countries have not responded adequately to people's needs. [24] Telemedicine could be a way to bridge this gap but is not necessarily a panacea.

Telemedicine may be a more effective way to screen for diabetic retinopathy than traditional methods, a recent study has suggested. Lead study investigator Steven Mansberger, MD, MPH, of Devers Eye Institute in Portland, Ore., believes telemedicine can also save ophthalmologists the time and aggravation of examining the large majority of diabetic patients who don't require their treatment.[25]

The project will prevent missing some patients in the early stage of retinopathy to prevent loss of vision, it will also improve the services provided in the diabetic clinics whether in Primary Health Care Services Sector or Hospital Services Sector as well as reduce the referral load on Dubai Hospital.

Retinal Camera is an instrument for photographing the ocular fundus. A fundus camera is a specialized low power microscope with an attached camera. It's optical design is based on indirect ophthalmoscope.

Retinal Camera Screening Procedure is to standardize practice of retinal screening using digital retinal camera by competent nursing staff.

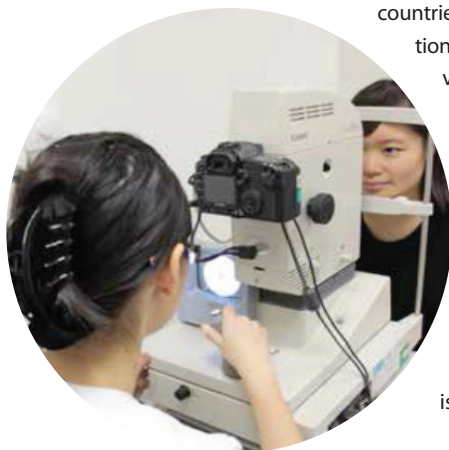Required Items:

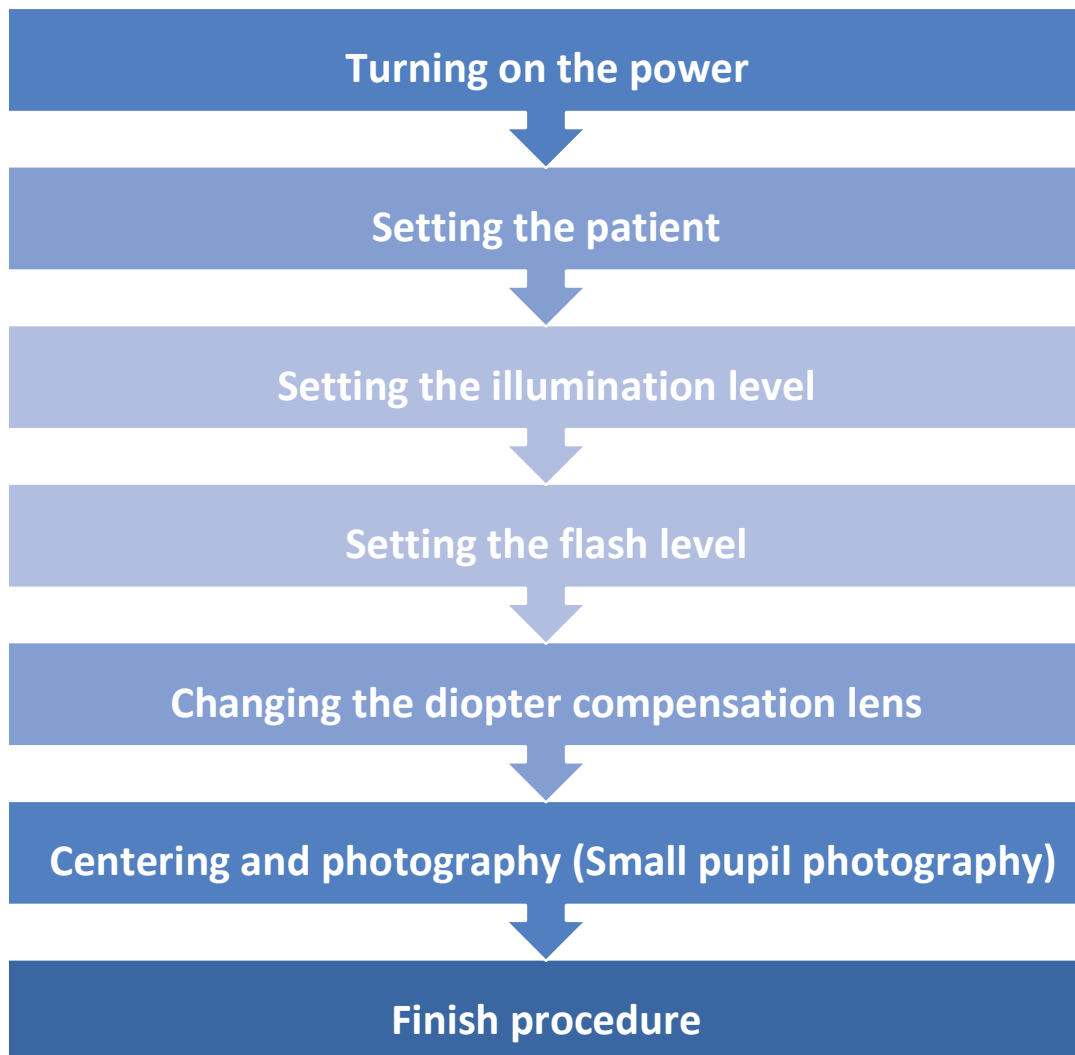
- Digital retinal camera
- PPE
- Hand rub
- Facial tissues

The patient is escorted by the DM link nurse and positioned appropriately and face the retinal camera. A brief explanation of the procedure is given again as the patient's cooperation during the process is key to securing quality digital images of the retina.

The patient is asked not to blink during the photography and to fixate on a green light when looking at the retinal camera. This maximizes the clarity of the retinal images. Photographs are taken of the optic disc and the macula in each eye. This takes 20–25 seconds. Two color photographs are taken of each eye.

The Nurse will operate the machine by using the Basic Operations of the Non-Mydriatic Retinal Camera TRC-NW8. [26] Flow of Operation as bellow graph:





Diabetic Retinopathy Diagnostic Approach

History: [1]

A complete history including duration and type of diabetes, medical history (i.e., obesity, renal disease, hypertension, serum lipid levels, pregnancy, past glycaemic control), ocular history (i.e., trauma, surgery), and medication history is recommended.

Most patients are asymptomatic or have symptoms unrelated to retinopathy, such as fluctuation in vision with blood glucose levels or as a symptom of cataracts. Visual disturbances may occur later in disease (e.g., floaters). Symptomatic patients may have either gradual vision loss (caused by macular oedema) or acute vision loss (caused by vitreous haemorrhage).

Clinical examination: [1]

Eye examination should be performed using an assessment of visual acuity, intraocular pressure, and stereoscopic biomicroscopy or direct ophthalmoscopy. Disease is usually symmetrical between the eyes.

Clinical signs of **mild to moderate non-proliferative diabetic retinopathy (NPDR)** include microaneurysms, intraretinal haemorrhage, cotton wool spots, and lipid exudates.

Severe non-proliferative retinopathy is characterised by venous beading, intraretinal microvascular abnormalities, and more widespread intraretinal haemorrhage. Cotton wool spots may also be present.

Non-proliferative retinopathy may progress to proliferative diabetic retinopathy (PDR), characterised by optic disc or retinal neovasculari-

sation, pre-retinal or vitreous haemorrhage, and intraretinal microvascular abnormalities. Venous beading and cotton wool spots are also common.

Eyes with untreated or inadequately treated proliferative retinopathy may progress to severe proliferative diabetic retinopathy with features such as traction retinal detachment and traction-rhegmatogenous retinal detachment.

Intraretinal oedema may involve the central retina, causing macular oedema, which appears as elevation or thickening of the central macula on stereoscopic evaluation.

Macular oedema may occur in NPDR or PDR. Macular oedema is described as clinically significant or non-clinically significant, and centre-involving or non-centre-involving.

None of these signs is diagnostic for diabetic retinopathy, and all may occur in other conditions. However, diffuse bilateral posterior pole involvement with such signs in a patient with diabetes usually suggests diabetic retinopathy.

There are certain eye conditions that have protective effect against diabetic retinopathy such as high level of myopia. So don't depend on presence of diabetic retinopathy in such conditions to screen for other diabetes complications.[27]

Diabetic Retinopathy Disease Severity Scale And International Diabetic retinopathy Severity Scale [22]

Disease Severity Level	Findings Observable upon Dilated Ophtalmoscopy
No apparent retinopathy	No abnormalities
Mild NPDR	Microaneurysms only
Moderate NPDR	More than just microaneurysms but less than severe NPDR
Severe NPDR: US Definition	Any of the following (4-2-1 rule) and no signs of proliferative retinopathy: <ul style="list-style-type: none"> Severe intraretinal hemorrhages and microaneurysms in each of four quadrants definite venous beading in two or more quadrants Moderate IRMA in one or more quadrants
Severe NPDR: International Definition	Any of the following and no signs of proliferative Retinopathy: <ul style="list-style-type: none"> Severe intraretinal hemorrhages and microaneurysms in each four quadrants Definite venous beading in two or more quadrants Prominent IRMA in one or more quadrants
PDR	One or both of the following: <ul style="list-style-type: none"> Neovascularization Vitreous/preretinal hemorrhage

Ancillary tests: [1]

Other tests that may be used to confirm diagnosis include:

- **Digital photographs of the fundus:** these should be ordered at baseline evaluation and when significant change is perceived in the fundus findings.
- **Optical coherence tomography:** should be ordered if there are signs of diabetic maculopathy, haemorrhage, microaneurysms, lipid

exudates, or thickening in the macular area, or unexplained visual loss.

- **Fluorescein angiography:** this can identify macular leakage, capillary non-perfusion, and new vessels.[28]
- **B scan ultrasonography:** this can identify retinal detachment in eyes with vitreous haemorrhage or other media opacity.

Differential Diagnosis: [1]

Condition	Differentiating signs/symptoms	Differentiating tests
1. Ocular ischemic syndrome:	<ul style="list-style-type: none"> • commonly presents with amaurosis fugax and gradual or sudden visual loss. • Vision may be poor, intraocular pressure may be abnormally high or low, and anterior segment neovascularisation is a common feature. • Commonly unilateral, predominantly haemorrhagic, and often involves equatorial and anterior retina rather than the posterior pole. • Check for carotid pulse that will be weak or absent and for carotid bruit. 	<ul style="list-style-type: none"> • Fluorescein angiography shows delayed arterial filling in affected eyes. • Doppler imaging may show carotid stenosis and ophthalmic artery flow reversal.
2. Radiation retinopathy	<ul style="list-style-type: none"> • Typically occurs in people with a history of radiation exposure and without diabetes. • Signs of an irregular pattern of capillary leakage and non-perfusion are present. 	<ul style="list-style-type: none"> • No differentiating tests; exposure to radiation should be elicited from the history.
3. Retinal Venous Occlusion	<ul style="list-style-type: none"> • Typically produces acute visual loss in one eye, and retinal signs (i.e., haemorrhage, cotton wool spots, macular oedema, neovascularisation) are limited to the eye and to the territory of the occlusion. • Central retinal vein occlusion typically involves the posterior pole, but if a branch vein is occluded, signs are limited to the segment of retina drained by the vein, and it is usually possible to identify the point of occlusion where an artery crosses anterior to a vein. 	<ul style="list-style-type: none"> • Fluorescein angiography is effective in characterising the distinctly localised nature of vascular abnormality in retinal venous occlusion.
4. Hypertensive retinopathy	<ul style="list-style-type: none"> • Systolic and diastolic pressures are markedly elevated. • Associated with acute visual disturbance, with optic disc swelling (which is uncommon in diabetic retinopathy) and macular oedema often in the form of a macular exudate star. • It may involve the posterior pole of both eyes, but signs of axoplasmic hold-up (i.e., cotton wool spots and optic disc oedema) tend to dominate the fundus appearance. 	<ul style="list-style-type: none"> • Fluorescein angiography reveals arteriolar non-perfusion, rather than capillary non-perfusion as in diabetic retinopathy

Diabetic Retinopathy Management

Treatment: [1]

The following table summarize frequency of repeating retinal phtotography and follow up according to stage of retinopathy and mo-
dality of treatment for each type: [22]

Severity of Retinopathy	Presence of Macular Edema (ME)	Follow-up (months)	Panretinal Photocoagulation (Scatter Laser)	Focal and or Grid Laser *	Intravitreal Anti VEGF Therapy
Normal or minimal NPDR	No	12	No	No	No
Mild NPDR	No	12***	No	No	No
	ME	4-6	No	No	No
	CSME **	1	No	Sometimes	Sometimes
Moderate NPDR	No	12	No	No	No
	ME	3-6	No	No	No
	CSME**	1	No	Sometimes	Sometimes
Severe NPDR	No	4	Sometimes	No	No
	ME	2-4	Sometimes	No	No
	CSME**	1	Sometimes	Sometimes	Sometimes
Non high risk PDR	No	4	Sometimes	No	No
	ME	2-4	Sometimes	No	No
	CSME**	1	Sometimes	Sometimes	Sometimes
High risk PDR	No	4	Recommended	No	Alternative
	ME	4	Recommended	Sometimes	Usually
	CSME**	1	Recommended	Sometimes	Usually

Anti-VEGF= anti-vascular endothelial growth factor; CSME=Clinically significant macular edema, ME= non-clinically significant macular edema; NPDR= non-proliferative diabetic retinopathy, PDR=proliferative diabetic retinopathy.

*Adjunctive treatments that may be considered include intravitreal corticosteroid or anti-VEGF agents (off-label use, except aflibercept and ranibizumab). Data from the Diabetic Retinopathy Clinical Research Network in 2011 demonstrated that, at two years of follow up, intravitreal ranibizumab with prompt or deferred laser resulted in greater visual acuity gain and intravitreal triamcinolone acetonide plus laser also resulted in greater visual gain in pseudophakic eyes compared with laser alone. Individuals receiving the intravitreal injections of anti-VEGF agents may be re-examined as early as one month following injection.

**exceptions include hypertension or fluid retention associated with heart failure, renal failure, pregnancy, or any other causes that may aggravate macular edema. Deferral of Photocoagulation for a brief period of medical treatment may be considered in these cases. Also deferral of CSME treatment is an option when the center of the macula is not involved., visual acuity is excellent, close follow-up is possible, and the patient understands the risks.

***Or at shorter intervals if signs approaching those of severe NPDR appear.

Severe PDR:

Patients with PDR not amenable to pan-retinal photocoagulation with or without macular laser therapy due to non-clearing vitreous hemorrhage obstructs fundus visualization should be referred for vitrectomy. Studies showed it's effectiveness.[1]

Complications: [1]

Complications of treatment of diabetic retinopathy

- **Post-vitrectomy cataract**

Eyes undergoing vitrectomy surgery commonly develop cataracts, typically **approximately 2 years later**

- **Neovascular glaucoma**

Post-vitrectomy haemorrhage

- **Macular oedema post-pan-retinal photocoagulation**
- **Visual field loss post-pan-retinal photocoagulation**
- **Para-central visual loss post-macular laser therapy**

Prognosis: [1]

Diabetic retinopathy is a chronic, progressive disease. Patients treated with macular laser therapy for diabetic macular oedema may show recurrence in the same or other eye. Treatment is usually limited to areas of retinal thickening, and untreated areas may develop oedema. Visual loss may develop despite treatment.

Patients treated with pan-retinal photocoagulation for proliferative diabetic retinopathy (PDR) are less likely to lose vision through vitreous haemorrhage than those who are untreated. Although haemorrhage can occur despite treatment, many patients reach a steady state in which fibro vascular proliferation ceases.

Eyes that have undergone vitrectomy commonly show little post-operative progression of retinopathy.

COUNSELLING: [29]

Patient education and counselling plays an important role in management of diabetic patients, in physicians' clinics as well as in the eye clinics. Patients with sight threatening retinopathy need additional counselling on impact on vision as well as retinal treatment options.

- ◇ Counselling on diabetic retinopathy is required as soon as diabetes is diagnosed and retinal screening commenced (**Level A**).
- ◇ Patient education plays an important role in management of retinopathy as increased awareness is linked with motivation. Ophthalmic consultation provides an opportunity to explain what retinopathy is, why it develops, what can be done to prevent progression and reduce the risk of blindness. Such counselling may improve compliance with screening and clinic visits. (**Level B**)
- ◇ Careful explanation of the risks and benefits of laser therapy is required as it is commonly assumed that such therapy will improve vision. (**Level A**)
- ◇ Detailed discussion and explanation about potential intraocular pharmacologic interventions is necessary, emphasizing the need for repeated and frequent attendance for further interventions to maintain benefit of the therapy. (**Level A**)
- ◇ Ophthalmologists and practitioners need to be aware of psychological need of their diabetic patients. Psychological support for children and adults with diabetes is recommended. In children, this should include eating disorders, behavioral, emotional problems. In adults, this should include anxiety, depression and eating disorders. (**Level B**)

Diabetic Retinopathy Referral Guide

For Family Physicians Guidance referral to Specialist: [30]

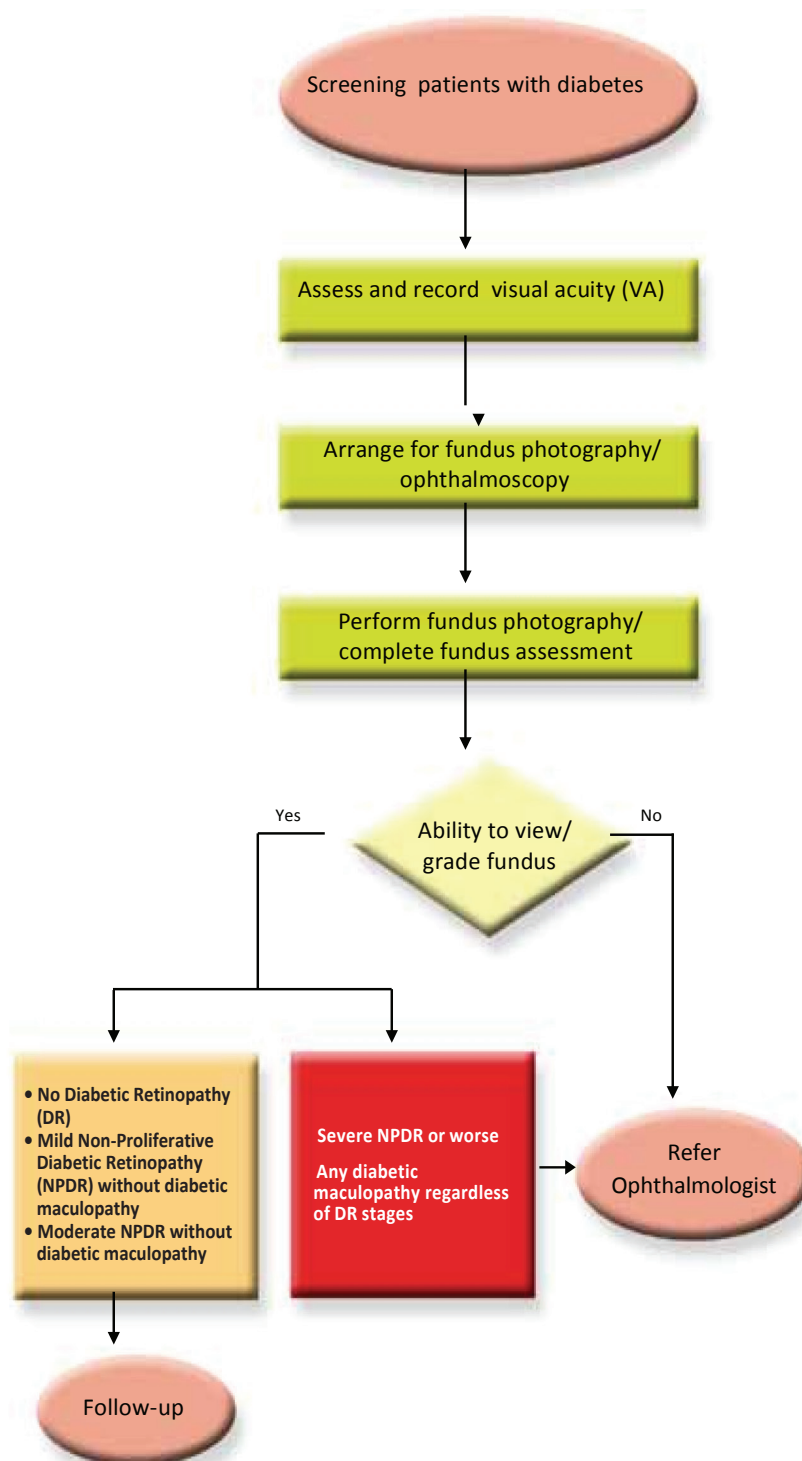
- Proliferative diabetic retinopathy (PDR): requires urgent referral.
- Severe non-proliferative diabetic retinopathy (NPDR): requires routine referral.
- Vitreous hemorrhage: requires urgent referral.

- Macular oedema: requires routine referral.

NB. Normal retinal image, mild and moderate NPDR images will be followed by family physician and repeated annually.

Diabetic Retinopathy Screening Guide in Primary Health Care

Below figure is Guidance for family physicians for process of screening for diabetic retinopathy: [31]



References

- 1- BMJ Best Practice. Diabetic Retinopathy. Updated May 04,2016
- 2- Klein R, Klein BE, Moss SE, et al. The Wisconsin Epidemiological Study of Diabetic Retinopathy II. Prevalence and risk of diabetic retinopathy when age at diagnosis is less than 30 years. Arch Ophthalmol. 1984;102:520-526. Abstract
- 3- Klein R, Klein BE, Moss SE, et al. The Wisconsin Epidemiological Study of Diabetic Retinopathy. III. Prevalence and risk of diabetic retinopathy when age at diagnosis is 30 or more years. Arch Ophthalmol. 1984;102:527-532. Abstract
- 4- Klein R, Klein BE, Moss SE, et al. The Wisconsin Epidemiological Study of Diabetic Retinopathy. XIV. Ten-year incidence and progression of diabetic retinopathy. Arch Ophthalmol. 1994;112:1217-1228. Abstract
- 5- Varma R, Torres M, Pena F, et al. Prevalence of diabetic retinopathy in adult Latinos: the Los Angeles Latino eye study. Ophthalmology. 2004;111:1298-1306. Abstract
- 6- Roy MS. Diabetic retinopathy in African Americans with type 1 diabetes: the New Jersey 725. 1. Methodology, population, frequency of retinopathy, and visual impairment. Arch Ophthalmol. 2000;118:97-104. Abstract
- 7- Wild S, Roglic G, Green A, et al. Global prevalence of diabetes: estimates for the year 2000 and projections for 2030. Diabetes Care. 2004;27:1047-1053. Full text Abstract
- 8- <http://forum.alrams.net/showthread.php?t=506148>
- 9- IDF Diabetes Atlas 2015
- 10- <https://www.aao.org/topic-detail/diabetic-retinopathy--middle-east-north-africa>
- 11- Cinar Y, Senyol AM, Duman K. Blood viscosity and blood pressure: role of temperature and hyperglycemia. Am J Hypertens. 2001;14:433-438. Abstract
- 12- Pecsvarady Z, Fisher TC, Darwin CH, et al. Decreased polymorphonuclear leucocyte deformability in NIDDM. Diabetes Care. 1994;17:57-63. Abstract
- 13- Vaidyula VR, Boden G, Rao AK. Platelet and monocyte activation by hyperglycemia and hyperinsulinemia in healthy subjects. Platelets. 2006;17:577-585. Abstract
- 14- Forrester JV. Mechanisms of new vessel formation in the retina. Diabet Med. 1987;4:423-430. Abstract
- 15- Rassam SM, Patel V, Kohner EM. The effect of experimental hypertension on retinal vascular autoregulation in humans: a mechanism for the progression of diabetic retinopathy. Exp Physiol. 1995;80:53-68. Full text Abstract
- 16- Diabetes Control and Complications Trial Research Group. Clustering of long-term complications in families with diabetes in the diabetes control and complications trial. Diabetes. 1997;46:1829-1839. Abstract
- 17- Javitt JC, Aiello LP. Cost-effectiveness of detecting and treating diabetic retinopathy. Ann Intern Med. 1996;124:164-169. Abstract
- 18- Singer DE, Nathan DM, Fogel HA, et al. Screening for diabetic retinopathy. Ann Intern Med. 1992;116:660-671. Abstract
- 19- Diabetic Retinopathy Study Research Group. Photocoagulation treatment of proliferative diabetic retinopathy. Clinical application of Diabetic Retinopathy Study (DRS) findings, DRS report number 8. Ophthalmology. 1981;88:583-600. Abstract
- 20- Early Treatment Diabetic Retinopathy Study Research Group. Treatment techniques and clinical guidelines for photocoagulation of diabetic macular edema. ETDRS report number 2. Ophthalmology. 1987;94:761-774. Abstract
- 21- Bailey CC, Sparrow JM, Grey RH, et al. The National Diabetic Retinopathy Laser Treatment Audit. III. Clinical outcomes. Eye. 1999;13:151-159. Abstract
- 22- American Academy of Ophthalmology. Preferred practice pattern: diabetic retinopathy. February 2016. <http://one.aao.org> (last accessed 19 April 2016). Full text
- 23- Early Treatment Diabetic Retinopathy Study Research Group. Grading diabetic retinopathy from stereoscopic color fundus photographs: an extension of the modified Airlie House classification. ETDRS report number 10. Ophthalmology. 1991;98(5 suppl):786-806. Abstract
- 24- Telemedicine in Primary Health Care: The Road Ahead. Int J Prev Med. 2013 Mar; 4(3): 377-378. <http://www.ncbi.nlm.nih.gov/pmc/articles/PMC3634179/>
- 25- How telemedicine is changing retinal care, App-based diagnostics are expanding screenings and treatments By Bill Kekevan, Senior Associate Editor. Ophthalmology Management, Volume: 17 , Issue: August 2013, page(s): 44 - 46 48
- 26- INSTRUCTION MANUAL NON-MYDRIATIC RETINAL CAMERA TRC-NW8 Topcon
- 27- Can Myopia Delay Diabetic Retinopathy? <https://www.reviewofoptometry.com/article/can-myopia-delay-diabetic-retinopathy>
- 28- Pecsvarady Z, Fisher TC, Darwin CH, et al. Decreased polymorphonuclear leucocyte deformability in NIDDM. Diabetes Care. 1994;17:57-63. Abstract
- 29- The Royal College of Ophthalmologists, Diabetic Retinopathy Guidelines December 2012
- 30- Public Health England. Diabetic eye screening: commission and provide. January 2015. <https://www.gov.uk/> (last accessed 19 April 2016)
- 31- National Institute for Clinical Excellence. Management of Type 2 diabetes. Retinopathy screening and early management London: NICE; 2002



40 years
of experience

partnering with more than 50 corporations
among the world's top 500

- **Human Resources Consultancy:** Human Resources
(Leadership Development, Executive Search and Training)
- **Healthcare Communications**
- **CME Programs & Medical Publishing**

USA | Canada | Europe | Middle East | North Africa

5 Konitsis Street, Marousi, 151 25 Athens, Greece www.groupccm.com
Tel: + 30 (210) 614 6560, Fax: + 30 (210) 8061765 E-mail: info@groupccm.com

CCM/7135



Published by: CCM Middle East s.a.r.l. P.O. Box 61145, 5 Konitsis str, Maroussi, Athens 15125 Greece.
Tel.: (+30) 210 6146560, Fax: (+30) 210 8061765, Email: info@groupccm.com